



International Journal of Pharma Research and Health Sciences

Available online at www.pharmahealthsciences.net



Case Study

Tetramelia: A Rare Case Presentation

Ashfaq ul Hassan *, Ghulam Hassan ¹, Shifan Khandey ², Sunanda Raina ³

* Sheri Kashmir Institute of Medical Sciences College Bemina, Srinagar, Kashmir, India

¹Department of Anatomy, Govt Medical College Srinagar, Kashmir, India

²Girls Dubai Medical College, Dubai.

³Department of Anatomy, Govt Medical College Jammu, Kashmir, India

ARTICLE INFO

A B S T R A C T


Received: 01 Oct 2014
Accepted: 23 Oct 2014

Congenital defects of the limbs are rare. Amelia is an extremely rare condition nowadays with complete absence of limbs. The evidence of absence of the limbs was apparent at birth. Both upper limbs as well as lower limbs were absent at birth. The couple had a non consanguineous marriage and there was no report of any teratogen intake during pregnancy.

Key words: Congenital, Thalidomide, Syndrome, Teratogen

1. INTRODUCTION

In humans complete absence of all limbs two upper limbs and two lower limbs is called as tetramelia. The absence may affect one or more limbs. It can be sporadic or acquired defect and can present as a single entity or may be associated with other anomalies. The rarity of this anomaly with the declining use of thalidomide a drug used in past inclined towards the development of this article. ^{1,2}



www.pharmahealthsciences.net

Quick Response Code

Corresponding author *
Dr Ashfaq ul Hassan
Lecturer Clinical Anatomy Sheri Kashmir Institute of Medical Sciences College Bemina, Srinagar Kashmir India
E Mail: ash Hassan@rediffmail.com

2. TEXT

This case was reported from a pregnant female of 32 years having first child in which the defect seen was absence of the limbs apparent at birth at 30 weeks. It was observed that both upper limbs as well as lower limbs were absent at birth. The couple had a non consanguineous marriage and there was no report of any teratogen intake during pregnancy. The mother was a non diabetic, non hypertensive, non alcoholic, no significant history of any serious drug addiction. The father was aged 33 years and was a smoker, non hypertensive, non alcoholic, and no significant history of any serious drug addiction. TORCH Screening of mother was negative along with the HIV status which was confirmed negative. During the course of pregnancy the female was taking calcium supplements. The female was from a rural background and had just one USG done previously at early stages of gestation showing an embryonic sac. There was no serious follow up and at the time of birth the anomaly was noticed.³⁻⁵

The inheritance pattern of Amelia can be sporadic or follow autosomal recessive or x linked dominant traits. It has been associated with the use of thalidomide, alcohol and multiple teratogens.

The effects of drugs taken by the mother vary considerably, especially in relation to the time in pregnancy when they are taken. Miscarriage or congenital malformations result from maternal ingestion of teratogenic drugs during the period of organogenesis. Maternal medications taken later, particularly during the last few weeks of gestation or during labor, tend to affect the function of specific organs or enzyme systems, adversely affecting the neonate rather than the fetus.^{6,7}

It has been observed that the most essential and the most critical period for the proper development of limbs is from 24 to 36 days after fertilization. This fact

has been based on multiple clinical studies of infants exposed to thalidomide which is a potent human teratogen, during the embryonic period. Exposure to this teratogen before day 33 has been seen to cause mild to severe limb defects, such as amelia which is the absence of limbs. It has been seen that most severe limb anomalies occurred from 1950 to 1970 as a result of maternal ingestion of the potent teratogen thalidomide. As a result the drug thalidomide is absolutely contraindicated in women of child-bearing age. Other teratogens effecting limb development are cocaine, ethanol, heroin and chorionic villus sampling. Major limb anomalies appear approximately twice in 1000 newborns. Limb anomalies can vary from simple polydactyly to absence of limbs. Most of these defects are caused by genetic factors. Molecular studies have implicated gene mutation (Hox gene, BMP, Shh, Wnt7, En-1) in some cases of limb defects. There is failure of formation of limb bud. In the partial absence i.e. phocomelia, there is partial development of limb bud. The severe forms can be particularly associated with deformities of cardiovascular system, urogenital system and pulmonary symptoms.

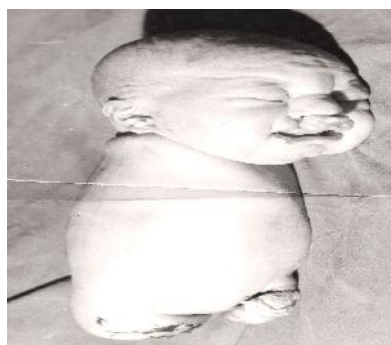

Fig 1: A Case of Tetramelia

Mechanisms of teratogenesis include cell death without reparative regeneration; mitotic delay; delayed differentiation; physical or vascular constraining; reduced histogenesis secondary to cell depletion, necrosis, calcification, or scarring; inhibited cellular migration; and inflammation. Many mechanisms occur

secondary to chromosomal or DNA damage and poor molecular repair.

It has been observed that the limb anomalies of different types are associated with CHARGE Syndrome, Di George Syndrome, VACTERL anomaly, David O Callaghan Syndrome.

The various reasons for limb defects is the antiangiogenic effects, changes in gene expression, DNA Mutations, limb bud distilization and induction of cell death.

3. CONCLUSION

Limb anomalies are associated with syndromic and non syndromic clinical syndromes and a look out for associated anomalies is warranted in case of severe limb anomalies.

4. REFERENCES

1. Smithells RW, Newman CG. Recognition of thalidomide defects. *J Med Genet* 1992; 29(10):716-723.
2. Bruyere HJ, Jr, Viseskul C, Opitz JM, Langer LO, Jr, Ishikawa S, Gilbert EF. A fetus with upper limb amelia, "caudal regression" and Dandy-Walker defect with an insulin-dependent diabetic mother. *Eur J Pediatr* 1980; 134(2):139-143.
3. Bod M, Czeizel A, Lenz W. Incidence at birth of different types of limb reduction abnormalities in Hungary 1975-1977. *Hum Genet* 1983;65(1):27-33.
4. Källén B, Rahmani TM, Winberg J. Infants with congenital limb reduction registered in the Swedish Register of Congenital Malformations. *Teratology* 1984; 29(1):73-85.
5. Morey MA, Higgins RR. Ectro-amelia syndrome associated with an interstitial deletion of 7q. *Am J Med Genet* 1990; 35(1):95-99.
6. Pauli RM, Feldman PF. Major limb malformations following intrauterine exposure to ethanol: two

additional cases and literature review. *Teratology* 1986; 33(3):273-280.

7. Van Allen MI, Curry C, Walden CE, Gallagher L, Patten RM. Limb-body wall complex: II. Limb and spine defects. *Am J Med Genet* 1987; 28(3):549-565.