



International Journal of Pharma Research and Health Sciences

Available online at [www.pharmahealthsciences.net](http://www.pharmahealthsciences.net)



## Original Article

# Hepatoprotective Effect of *Solanum xanthocarpum* in Paracetamol Induced Hepatic Damage in Experimental Animals

V Sivakumar<sup>1,\*</sup>, A Mohamed Sadiq<sup>1</sup>, M S Dhana Rajan<sup>2</sup>, M Jayanthi<sup>1</sup>, E Paari<sup>1</sup>

<sup>1</sup> P. G. and Research Department of Biochemistry, Adhiparasakthi College of Arts and Science, Kalavai, Tamil Nadu, India.

<sup>2</sup> P. G. and Research Department of Biochemistry, Jaya College of Arts and Science, Thiruninravur, Tamil Nadu, India.

### ARTICLE INFO

### A B S T R A C T

Received: 05 Mar 2014

Accepted: 10 Apr 2014

**Aim:** The present study aims to evaluate the hepatoprotective effect of ethanol extract of *Solanum xanthocarpum* (EESX) leaf on paracetamol induced hepatic damaged in experimental rats. **Materials and methods:** Paracetamol (3g/kg, P.o) was administered a single dose to induce hepatotoxicity. EESX (200mg and 400mg/kg, P.o) and silymarin (25mg/kg, P.o) were administered once daily for 8 days. The degree of hepatoprotection was measured using serum transaminases (AST and ALT), alkaline phosphatase, total protein and total bilirubin levels. Histopathological changes of liver sample were also observed. **Results:** EESX treatment showed significant dose dependent restoration of serum enzymes, total protein and bilirubin levels. Improvements in hepatoprotection and morphological and histopathological changes were also observed in ethanol extract of *Solanum xanthocarpum* treated rats. **Conclusion:** The result of this study strongly indicated that ethanol extract of *Solanum xanthocarpum* has got a hepatoprotective action against paracetamol induced hepatic damage in rats.

**Key words:** *Solanum xanthocarpum*, hepatoprotective, paracetamol, silymarin, histopathology

## 1. INTRODUCTION

The liver is a vital important organ, playing a pivotal role in intermediary metabolism and regulating various physiological processes in the body. It possesses great capacity to detoxicate toxic substances and synthesized useful principles.<sup>1</sup> Liver diseases are mainly caused by toxic chemicals, excess consumption of alcohol, infections, environmental pollutants drugs and

### Corresponding author \*

Dr.V. Sivakumar, Adhiparasakthi College of Arts and Science, Kalavai, Tamil Nadu, India

autoimmune disorders. Most hepatotoxic chemicals damage liver cells mainly by inducing lipid peroxidation and other oxidative damages.<sup>2</sup>

Recently there is a greater global interest in non synthetic, natural drugs derived from plant/ herbal sources due to better tolerance and minimal adverse drug reactions.<sup>3</sup> No effective measures are available for the treatment of liver disease in modern medicine so for herbal drugs, used in Indian system of medicine are however a claimed to be effective and safe in such ailments.<sup>4</sup>

*Solanum xanthocarpum* Schrad. & Wendl. is known as Indian night shade or yellow berried night shade plant. The Common name is Kantakari, synonym *Solanum surattense* and it belongs to family *Solanaceae*. It plays an important place among medicinal herbs, (especially, for the treatment of cough) in India since ancient times. The plant found well versed in India, often in waste places, on roadsides and in open space. It is usually spreading or diffused perennial, woody at base, 2-3 m in height. The young branches are densely covered with star-shaped hairs. The zig-zag branches, and covered with yellow, sharp, shining prickles. The leaves are up to 10 cm in length, their midribs and other nerves with sharp yellow prickles. The flowers are purple in nature, about 2 cm long, found has small bunch opposite to the leaves. The fruits are glabrous, globular drooping berries, 1.5-2 cm, yellow or white with green veins, surrounded by enlarged calyx.<sup>5</sup> Kantakari is bitter and pungent in taste and has hot potency. It possesses light and dry attributes. Kantakari is useful in wide range of diseases. It is more commonly used in the diseases like bronchial asthma, cough, worms etc. The fruits facilitate the seminal ejaculation, alleviate worms, itching, and fever and reduce fats.<sup>6</sup>

The whole plant is used for medicinal purpose including of fruits and roots. The powder form of

kantakari with oils is mixed well and used externally to alleviate nasal disorders. And also, nasal administration of kantakari is beneficial in migraine, and headache. The dried fruits are smoked in the form of cigarette and the smoke held up in the mouth cavity for some time ameliorates the dental infections. The fumigation of kantakari is helpful in piles. The paste applied on swollen and painful joints in arthritis, reduces the pain and swelling effectively.<sup>7</sup> To the best of our knowledge there was lack of scientific reports available in support of its traditional claim of hepatoprotective potentials. Therefore, present study was designed to evaluate the effect of *Solanum xanthocarpum* leaf ethanol extract against paracetamol induced hepatic damaged in experimental rats.

## 2. MATERIALS AND METHODS

### 2.1 Plant collection and Preparation of plant extract

Fresh and matured *Solanum xanthocarpum* medicinal plant was collected from campus garden of Adhiparasakthi Agricultural College in kalavai, India in December 2012. The plant material was identified and authenticated in the plant anatomy research centre, Chennai. The plant voucher specimen number: PARC/2013/2025 was deposited in the center herbarium. The freshly collected leaves (3kg) of *Solanum xanthocarpum* were dried and powdered. The powdered plant material (1200g) was macerated with petroleum ether, the marc was exhaustively extracted with 80% ethanol for three days. The extract was separated by filtration and concentrated on rota vapour and then dried in lyophilized under reduced pressure. The yield obtained was 180.50g of solid residue (yield 30.10%w/w).

### 2.2 Animals

The healthy adult male *wistar albino* rats (weighing 180 - 210g) were used in the experiments. Animals were housed in polypropylene cages at 22±2°C with relative humidity of 45- 55% under 12 hour's light and

dark cycle. They were feed with standard laboratory animal feed (Hindustan Lever Ltd., India) and water *ad libitum*. Ethical clearance was obtained from the Institutional Animal Ethical Committee, CPCSEA, India (Reg. No. 282/ac/09/CPCSEA).

### 2.3 Acute toxicity studies

Acute toxicity study was performed according to Organisation for Economic Co-operative and development guidelines No. 423.<sup>8</sup> *Wistar albino* rats of either sex were divided into six groups with six animals each. *Solanum xanthocarpum* ethanol extract was administered orally as single doses to rats at different dose levels of 250, 500, 1000, 1500, and 2000mg/kg b.w. Animals were observed individually during the first 30minutes and periodically during 24 hours, with special attention given during the first 4 hours and daily thereafter, for a total 14 days.

### 2.4 Experimental protocol

The rats were divided into five groups with six in each group. Group-I Animal were administrated a single daily dose of carboxymethyl cellulose (1ml of 1% W/V,p.o body weight) served as healthy control. Group-II Animals served as paracetamol control, which received paracetamol (3g/kg) as a single dose on day 8. Group-III Animals received ethanol extract of *Solanum xanthocarpum* (200mg/kg, p.o) once daily for 8 day. Group – IV animals received ethanol extract of *Solanum xanthocarpum* (400mg/kg, p.o) once daily for 8 days. Group – V Animals served as reference control and received standard drug silymarin using for treatment of liver damages (25mg/kg, p.o) once daily for 8 days. All groups except group I received paracetamol (3g/kg) as a single dose after 30min. of 8 day treatment of the herbal during. All the test drugs and paracetamol were administered orally by suspending in 0.5 % CMC solution. Animals were sacrificed by cervical dislocation, 48h after the last

dose of the drug. The liver samples were dissected and blood was collected.

### 2.5 Assessment of Liver function parameters

The blood was collected from carotid artery and allowed to clot and serum was separated at 2500rpm for 20min. and the collected serum was used for the assay of marker enzymes Aspartate aminotransferase (AST), Alanine aminotransferase (ALT) were estimated by the method of Reitman and frankel.<sup>9</sup> and Alkaline phosphatase (ALP) was determined by the method of Kind and King.<sup>10</sup>

### 2.6 Assessment of biochemical parameters

The biochemical parameters such as total protein were estimated by the method of Lowry.<sup>11</sup> The total bilirubin was estimated by the method of Molloy and Evelyn.<sup>12</sup>

### 2.7 Histopathological studies

For histological studies, the liver tissues were fixed with 10% phosphate buffer neutral formalin, dehydrated in graded (50-100%) alcohol and embedded in paraffin, thin sections (5µm) were cut and stained with routine hematoxylin and eosin (H & E) stain for photo microscopic assessment. The initial examination was qualitative, with the purpose of determining histopathological lesions in liver tissue.

### 2.8 Statistical analysis

The results are expressed as mean±SD. The data were analyzed by one way ANOVA followed by Dun net's test at level of significance was expressed as P<0.01 and P<0.001.

## 3. RESULTS AND DISCUSSION

### 3.1 Acute toxicity study

According to acute toxicity study the LD<sub>50</sub> value for the *Solanum xanthocarpum* ethanol extract of leaf is 200 mg/kg in rats. The extract administered at a dose of 2000mg/kg through oral did not show any adverse sign and symptoms of mortality during the observation period. Based on this observation the stating dose was

selected as 1/10<sup>th</sup> (200mg/kg) and 1/5<sup>th</sup> of (400mg/kg) 2000mg/kg, were taken in this study.

### 3.2 Effect of Ethanol extract of *Solanum xanthocarpum* on AST, ALT and ALP

In the present investigation, daily oral administration of *Solanum xanthocarpum* leaf ethanol extract was evaluated for the hepatoprotective activity using paracetamol induced hepato damaged in experimental rats.

Toxic metabolite of paracetamol, N- acetyl, P- benzoquinone imine, covalently interact with thiol groups in proteins and causes liver cell damage by causing depletion of glutathione levels and thiol proteins of liver and consequent stimulation of lipid peroxidation. Due to exhaustion of detoxifying agent glutathione, hepatocytes are vulnerable to the excess of toxic metabolite resulting into liver cell damages.<sup>13</sup>

Significantly hepatotoxicity was observed after 8<sup>th</sup> day administration of paracetamol, as indicated by increases in serum AST, ALT and ALP levels [Table 1].

**Table 1: Effects of ethanol leaf extract of *Solanum xanthocarpum* on liver function parameters under different experimental conditions**

Parameters	Normal control	Toxic control Paracetamol (3g/kg)	EESX (200mg/kg)+ Paracetamol (3g/kg)	EESX (400mg/kg)+ Paracetamol (3g/kg)	Silymarin (25mg/kg)+ Paracetamol (3g/kg)
AST (IU/L)	102.10±1.12	348.32±10.22*	163.14±2.231 <sup>a</sup>	121.11±1.311 <sup>b</sup>	112.21±4.187 <sup>b</sup>
ALT (IU/L)	40.21±4.12	210.23±22.10*	86.43±11.10 <sup>a</sup>	67.26±8.11 <sup>b</sup>	51.31±3.11 <sup>b</sup>
ALP (IU/L)	63.65±2.36	139.55±10.22*	79.42±3.32 <sup>a</sup>	72.42±6.54 <sup>b</sup>	67.67±2.11 <sup>b</sup>

EESX = Ethanol Extract of *Solanum xanthocarpum*, AST= Aspartate aminotransferase, ALT= Alanine aminotransferase, ALP= Alkaline phosphatase. Values are expressed as mean ±SD for six animals in each group. P values: \*<0.001 compared with respective control group I; P values: a<0.01, b<0.001 compared with group II (Paracetamol toxic control).

Indicating considerable hepatocellular injury. Hepatocellular necrosis leads to elevation of the serum marker enzymes, which are released from the liver into blood.<sup>14,15</sup>

The treatment of daily oral administration of ethanol extract of *Solanum xanthocarpum* at different dose level (200mg and 400mg/kg) was caused a subsequent recovery towards normalization comparable to the control group and standard drug silymarin received animals.

In the treatment of both concentration of *Solanum xanthocarpum* extract indicating that they were protective to hepatocytes and maintained normal levels physiology and further cause regeneration of damaged liver cells.

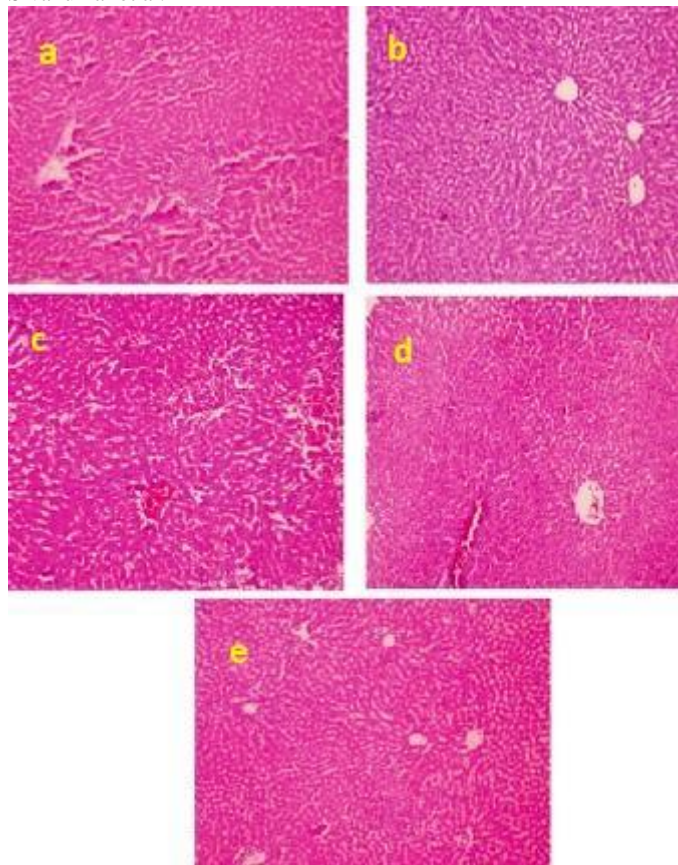
### 3.3 Effect of Ethanol extract of *Solanum xanthocarpum* on total protein and total bilirubin

In the present study, the hepatotoxic drugs, such as paracetamol, are known to cause marked elevation of serum level of enzymes and decrease in total serum protein was observed in rats, treated with paracetamol and may be associated with the turn may result in the decreased hepatic capacity to synthesise protein. The marked elevation in bilirubin in the serum of paracetamol-intoxicated rats.<sup>16</sup> After the treatment of ethanol extract of *Solanum xanthocarpum* in significantly increased in total protein and decreased total bilirubin concentrations when compared to control rats [Table 2]. The result of ethanol extract of *Solanum xanthocarpum* treatment was similar to that of the standard drug silymarin.

**Table 2: Effects of ethanol leaf extract of *Solanum xanthocarpum* on biochemical parameters under different experimental conditions.**

Parameters	Normal control	Toxic control Paracetamol (3g/kg)	EESX (200mg/kg)+ Paracetamol (3g/kg)	EESX (400mg/kg)+ Paracetamol (3g/kg)	Silymarin (25mg/kg)+ Paracetamol (3g/kg)
Total protein (g/dl)	6.91±0.01	2.81±0.42*	5.1±1.00 <sup>a</sup>	6.4±0.11 <sup>b</sup>	6.5±0.01 <sup>b</sup>
Total bilirubin (mg/dl)	0.72±0.12	3.61±0.22*	1.4±0.21 <sup>a</sup>	0.98±0.02 <sup>b</sup>	0.86±0.12 <sup>b</sup>

EESX = Ethanol Extract of *Solanum xanthocarpum*, Values are expressed as mean ±SD for six animals in each group. P values: \*<0.001 compared with respective control group I; P values: a<0.01, b<0.001 compared with group II (Paracetamol toxic control).



**Fig 1:** Histopathological of hepatic cells of (a) Normal control rat, (b) Paracetamol Toxic control (3g/kg), (c) Paracetamol +EESX (200mg/kg), (d) Paracetamol + EESX (400mg/kg), (e) Paracetamol + Silymarin (25mg/kg).

In different doses levels of ethanol extract of *Solanum xanthocarpum*, 400mg/kg showed maximum protection which was almost near comparable to these of the normal control and silymarin.

### 3.4 Histopathological observations

The histological observation basically supported the results obtained from serum enzyme assays. Liver of the normal control rats were without any pathological changes or abnormalities. Paracetamol control rats showed various degrees of pathological changes, starting from centrilobular necrosis of hepatic cells to central lobular fatty degeneration with inflammation. Section of liver taken from the rats treated with standard drug silymarin showed a hepatic architecture similar to that of normal showed a hepatic architecture similar to that normal control rats. In contrast, ethanol extract of *Solanum xanthocarpum* (200mg and

400mg/kg, p.o) attenuated the pathological changes and showed significant protection against paracetamol induced hepatic damage [Figure 1].

### 4. CONCLUSION

From the above result, it is clear that the ethanol extract of *Solanum xanthocarpum* has exhibited dose dependent activity; however the dose level of 400mg/kg, p.o, showed greater activity as compared to control and standard groups. Liver histopathologies images evidenced that ethanol extract of *Solanum xanthocarpum* attributed the hepatoprotective effects further investigation are required for the identification of activity construction responsible for the hepatoprotection.

### 5. REFERENCES

1. Sahani S. Evaluation of hepatoprotective efficacy of APCL-A polyherbal formulation *in vivo* in rats. *Indian Drugs* 1999;36: 628-32.
2. Boyd EH, Berezky GM. Liver necrosis from paracetamol. *Br J pharmacol* 1966; 26: 606-14.
3. Sivakumar V, Dhanarajan MS. Antioxidant effect of *Tinospora cordifolia* extract in alloxan induced diabetic rats. *Indian J Pharm Sci* 2010; 72(6):795-98.
4. Nadeem M, Dandiya PC, Pasha KV, Imran M, Balani DK, Vohora SB. Hepatoprotective activity of some herbal formulations available in India. *Indian drugs* 1996; 33:390-6.
5. Singh OM, Singh TP. Phytochemistry of *Solanum xanthocarpum*: an amazing traditional healer. *J Sci Ind Res* 2010; 69:732-40.
6. Kiritkar KR, Basu BD, *Indian medicinal plants*. 2nd ed. Dehradun: Bishen singh Mahendra Pal Singh; 2005. p.1759-62.
7. Kar DM, Maharana L, Pattnaik S, Dash GK. Studies on hypoglycaemic activity of *Solanum xanthocarpum* Schrad. & wendl. Fruit extract in rats. *J Ethnopharmacol* 2006; 108:251-56.

8. OECD. Guidelines for the testing of chemicals revised draft guideline 423: Acute oral toxicity. Paris: OECD; 2000.
9. Reitman S, Frankel S, A colorimetric method for the determination of Serum glutamate Pyruvate Transaminase and Serum Glutamate Oxaloacetate Transaminase. *Am J cli Path* 1957; 28:56-62.
10. Kind PR, King EJ. Determination of Serum Alkaline phosphatase. *J Cli Path* 1954;7: 132-6.
11. Lowry OH, Rosebrough NJ, Farr AL, Randall. PJ. Protein measurement with folin-phenol reagent. *J Bio Chem* 1951; 193: 265-75.
12. Mally HT, Evelyn KA. The determination of bilirubin with the photometric colorimeter. *J Bio Chem* 1937;119: 481- 90.
13. Dahlin D, Miwa G, Lu A, Nelson S. N-acetyl-P-benzoquinone imine: A cytochrome P-450-mediated oxidation product of acetaminophen. *Proc Natl Acad Sci* 1984;8:1327-31.
14. Moron MS, Depierre JW, Mannervik B. Levels of glutathione, glutathione reductase and glutathione-S-transferase activities in rat lung and liver. *Biochim Biophys Acta* 1979;582:76-78.
15. Gupta AK, Chitme H, Dass SK, Misra N. hepatoprotective activity of Rauwolfia serpentine rhizome in paracetamol intoxicated rats. *J Pharmacol toxicol* 2006;1: 82-8.
16. Saravanan R, Viswanathan P, Pugalendi KV. Protective effect of ursolic acid on ethanol-mediated experimental liver damage in rats. *Life Sci* 2006; 78:713-6.