



## Original Article

## Morphometry of Acromion Process: A Study of Indian Scapulae

Shilpa Gosavi<sup>1,\*</sup>, Surekha Jadhav<sup>2</sup>, Rajendra Garud<sup>1</sup><sup>1</sup> Dept of Anatomy, BVDU medical college, Pune, Maharashtra, India- 411043.<sup>2</sup> Dept of Anatomy, PDVVPF's Medical college, Ahmednagar, Maharashtra, India- 414111

## ARTICLE INFO

## A B S T R A C T

Received: 30 Aug 2015  
Accepted: 28 Oct 2015

**Objective:** Anatomic details and variations of shoulder region are important for diagnosis and management of corrective surgeries in this area. Acromion morphology is believed to play a key role in impingement syndrome and the pathogenesis of rotator cuff diseases. The present study was carried out with the purpose to collect the morphological data of acromion process in Indian population and to compare it with similar studies in other population.

**Experimental approach:** We studied 127 dry scapulae of unknown age and sex. Acromion processes were classified into Type I (flat), II (curved) and III (hooked). The length, breadth, anterior thickness, coraco-acromial distance, acromion-glenoid distance and the height of coraco-acromial arch was measured with the help of digital vernier caliper. The inclination of acromion was measured with the help of goniometer. **Findings and Discussion:** Type II acromion was observed in majority (81.88%), type I in 13.3% and type III in 4.7%. Mean coraco-acromial distance was  $26.9 \pm 5.6$  mm while mean acromio-glenoid distance was  $22.68 \pm 3.3$  mm. Mean height of coraco-acromial arch was  $16.54 \pm 2.8$  mm. The inclination of acromion was less on the right side as compared to the left side (Rt.  $-33.46^\circ$ , Lt.  $-43.4^\circ$ ).

**Conclusion:** Predominance of Type II acromion and bilateral symmetry in all other parameters was observed. When the results were compared with similar studies, differences were observed in most of the parameters. The results of the present study may be of help to the shoulder surgeons, Anthropologists and Anatomists.

**Key words:** Acromion, morphology, Scapula.

## 1. INTRODUCTION

The acromion projects forwards almost at right angle, from the lateral end of the spine of scapula. The lower border of the crest of the spine becomes continuous with the lateral border of the acromion at the acromial angle which forms a subcutaneous bony landmark.

## Corresponding author \*

Dr. Shilpa Gosavi, Dept. of Anatomy,  
Bharati Vidyapeeth Deemed University Medical College,  
Dhankawadi, Pune, Maharashtra, India. 411043  
E-mail - [sngosavi@yahoo.com](mailto:sngosavi@yahoo.com)

The medial border of the acromion is short and is marked anteriorly by a small oval facet directed upwards and medially for articulation with the lateral end of the clavicle. The tendon of supraspinatus passes below the overhanging acromion and is separated from it and from deltoid by the subacromial bursa.<sup>1</sup>

The anatomy of the acromion and related structures in the shoulder joint is of importance and useful to successfully carry out interpretation of images and surgical procedures in pathologies associated with this joint.<sup>2</sup> Acromion morphology is believed to play a key role in impingement syndrome and the pathogenesis of rotator cuff diseases.<sup>3</sup>

The variation of the acromion form has been studied by different authors.<sup>2-6</sup> Bigliani et al.<sup>4</sup> classified the acromion in type I (plane), type II (curved) and type III (hooked). The slope and length of the acromion and the height of the arch are most closely associated with degenerative changes.<sup>5</sup>

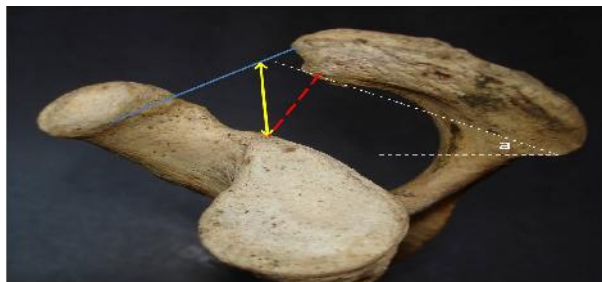
Anatomic details and variations of the region are important for diagnosis and treatment. Furthermore, to recognize that important parameters of the region may change according to the race, gender and lateralization will significantly increase the surgical achievement.<sup>6</sup>

The present study was carried out with the purpose to collect the morphological data of acromion process in Indian population and to compare it with similar studies in other population.

## 2. MATERIAL AND METHOD

We studied one hundred and twenty-seven dry scapulae (Right -52, Left- 75) available in the department of anatomy, after taking approval from the Ethical committee. The unbroken, intact adult scapulae of unknown age and sex were included in the study. Acromion processes were classified into Type I (flat), II (curved) and III (hooked) as suggested by Bigliani et al.<sup>4</sup>.

Following morphological parameters were measured using digital vernier caliper accurate up to 0.01 mm and the angular measurements were taken with the help of goniometer. (Fig.- 1)



**Fig 1:** Figure showing various measurements of acromion process. Blue line – Coraco-acromial distance, Yellow line – Height of coraco-acromial arch, Red dotted line – Acromio – glenoid distance,  $\alpha$  = Inclination of acromion

- The length of acromion process was measured as antero-posterior distance along the long axis
- The width was measured as the maximum distance between lateral and medial borders.
- Anterior thickness was measured at a point 1 cm posterior to anterior border and 1 cm medial to lateral border.
- The coraco-acromial ligament was simulated by a semi-rigid plastic strip and the shortest distance to the supraglenoid tubercle was measured as height of coraco-acromial arch (as described by Edelson and Taitz<sup>5</sup>)
- Distance between tips of coracoid and acromion processes was measured as C-A dist.
- Acromio-glenoid distance (A-G dist) was measured as distance between supraglenoid tubercle and inferior surface of acromion process.
- Inclination of acromion was measured as the angle between the line tangential to the inferior surface of acromion and horizontal plane.
- The length and the width of the articular facet for the lateral end of clavicle were also noted.

The data was analyzed with the help of SPSS 17, mean, standard deviation, Z value and t value were calculated.

### 3. RESULT

In a study of 127 dry scapulae of unknown sex and age from Indian population, Type II (curved) acromions were observed in majority (81.88%) of the scapulae. Type I acromions were present in 13.3% and type III in 4.7%.

The mean length of acromion was  $43.7 \pm 6$  mm and the width was  $22.78 \pm 2.7$  mm. Distance of the tip of acromion measured from the tip of coracoid process (C-A dist) was  $26.9 \pm 5.6$  mm, while acromio - glenoid distance (A-G dist) was  $22.68 \pm 3.3$  mm. Mean height of the coraco-acromial arch was  $16.54 \pm 2.8$  mm. The inclination of acromion was less on the right side as compared to the left side (Rt.  $-33.46^\circ$ , Lt.  $-43.4^\circ$ ) but the difference was not significant statistically ( $p > 0.05$ ).

**Table 1: Classification of Acromion**

Type	Rt.(n=52)	Lt( n=75)	Total (n=127)
I	04 (7.69%)	13 (17.33%)	17 (13.38%)
II	46 (88.46%)	58 (77.33%)	104 (81.88%)
III	02 (3.84%)	04 (5.33%)	06 (4.72%)

**Table 2: Anatomical parameters for acromion process**

Parameter	Rt.(n=52)	Lt( n=75)	Mean	Range	Z-value	P-value
Length	$44.3 \pm 5.89$	$43.1 \pm 6.11$	$43.7 \pm 6$	28.1 - 62.6	1.04	>0.05
Width	$23.08 \pm 2.74$	$22.48 \pm 2.82$	$22.78 \pm 2.78$	16.2 - 28.8	1.14	>0.05
Ant. Thickness	$6.73 \pm 1.28$	$7.07 \pm 1.23$	$6.9 \pm 1.25$	3.9 - 10.9	1.4	>0.05
C-A dist	$26.43 \pm 5.89$	$27.38 \pm 5.5$	$26.9 \pm 5.69$	2.9 - 46.8	0.85	>0.05
A-G dist	$23.08 \pm 3.17$	$22.28 \pm 3.45$	$22.68 \pm 3.31$	13.6 - 30.7	1.26	>0.05
Ht. of CCA	$16.71 \pm 2.82$	$16.38 \pm 2.9$	$16.54 \pm 2.85$	8.5 - 24.2	0.59	>0.05
Art. facet length	$13.56 \pm 2.73$	$14.07 \pm 2.63$	$13.81 \pm 2.78$	8.7 - 20.1	0.98	>0.05
Art. facet width	$8.58 \pm 5.5$	$7.69 \pm 1.89$	$8.13 \pm 3.69$	0.8 - 11.16	1.11	>0.05

Narrowest distance between coracoid and acromion process in the present study was measured as 16.8 mm whereas the narrowest distance between acromion and glenoid was 13.6 mm.

The articular facet for the lateral end of the clavicle had mean length of  $13.81 \pm 2.78$  mm and mean width as  $8.13 \pm 3.69$  mm.

### 4. DISCUSSION

During the evolution of the upper extremity, the scapula, more than any other bone of the shoulder girdle, reflects momentous alterations that have been brought about by increased functional demands of a prehensile limb. Changes in posture provided the stimulus which initiated the numerous morphologic changes. Gradual increase in the spine of the scapula and the acromion process during development from the pronograde to the orthograde. This change reflects the increasing importance of the deltoid muscle.<sup>7</sup>

Collipol et al<sup>2</sup> quoted that, the acromion morphology according to Epstein et al. appears to have a prediction value to determine the success of conservative medical treatment in some cases and the need for surgery in patients with joint impingement. Acromion of the hook type (Type III) was observed with two times greater frequency in patients with rotator cuff impingement syndrome.<sup>2</sup>

High incidence of Type II followed by type I and very low incidence of Type III scapulae was observed in the present study. The findings were similar to Sangiampong et al.<sup>8</sup> in Thai population, Musa et al.<sup>6</sup> in Turkish population and Saha et al.<sup>9</sup> in Indian population. However high incidence of Type II, followed by Type III and less number of Type I acromion was observed by Coskun et al.<sup>3</sup> in Turkish population and Schetino et al.<sup>10</sup> in Brazilian population.

**Table 3: Comparison of types of Acromion with some of the previous studies**

Type (%)	Sangiampong et al <sup>8</sup> (Thai)	Coskun et al <sup>3</sup> (Turkish)	Schetino et al <sup>10</sup> (Brazilia)	Musa et al <sup>6</sup> (Turkish)	Saha et al <sup>9</sup> (India)	Singh et al <sup>12</sup> (India)	Present study
I	3.2	10	5.20	37	28	22.5	13.3
II	93.5	73	57.9	48.7	67	38.8	81.88
III	3.2	17	36.9	13.7	05	38.8	4.72

The length of the acromion was  $43.7 \pm 6$  mm in the present study; the findings were similar to most of the earlier studies. (Table - 4) Edelson and Taitz<sup>5</sup> had observed that the thickness and width of Acromion have no correlation with degenerative changes. The width of the acromion in the present study did not show much difference when compared with other studies. The thickness of acromion observed by Paraskevas et al.<sup>11</sup> was more (8.8 mm) as compared to the present study (6.9 mm) and also another study in Indian population by Singh et al.<sup>12</sup> (6.6 mm).

**Table 4: Comparison of various parameters with some of the previous studies**

Parameter	Mansur et al <sup>13</sup> (Nepalese)	Paraskevas et al <sup>11</sup> (Greek)	Musa et al <sup>6</sup> (Turkish)	Coskun et al <sup>3</sup> (Turkish)	Singh et al <sup>12</sup> (Indian)	Present study (Indian)
Length	46.01	46.1	45.85	44.7	46.1	43.7
Width	26.93	22.3	23.02		23.2	22.78
Ant.		8.8			6.6	6.9
Thickness						
C-A dist	39.21	28.1	15.48	17.8	37.5	26.9
A-G dist	31.9	17.7			27.0	22.68
Ht. of CCA						16.54

The predominant theory for the impingement syndrome of the rotator cuff muscles classifies the contributing factors as anatomical and functional. The anatomical causes include the shape and the inclination of the acromion.<sup>11</sup> The Inclination of the acromion in the present study was  $33.46^{\circ}$  on the right side and  $43.4^{\circ}$  on the left side.

Sangiampong et al.<sup>8</sup> quoted that, difference in the development and morphology of acromion and the presence of anterior acromial spur and inferior acromioclavicular osteophytes decrease the volume of subacromial space, leading to impingement and the very close contact between the supraspinatus and the anterior inferior part of the acromion, occurring at  $90^{\circ}$  abduction in internal rotation. In the present study we found presence of acromial spur in three bones.

Some of the parameters of scapular morphometry vary with sex and age, which also has a clinical significance. Unfortunately, the data regarding age and the sex of the bones studied was not available and that we consider it as a weakness of this study

## 5. CONCLUSION

The results of the present study of 127 scapulae revealed that Type II (Curved) acromion was predominant. The bilateral symmetry was present in all the parameters observed. The length and width of acromion did not show much variation when compared with other populations but coraco-acromial distance and acromio-glenoid distance was variable. The results of the present study may be of help to the shoulder surgeons, Anthropologists and Anatomists.

## 6. ACKNOWLEDGEMENT

We acknowledge the suggestions and help by Dr. P. Vatsalaswamy, Prof. Dept. of Anatomy, Dr. D. Y. Patil medical college, Pimpri, Pune.

## 7. REFERENCES

1. Standring S. Gray's Anatomy: the Anatomical basis of clinical practice. Fortieth edition. Elsevier Ltd: London, UK. 2008.
2. Collipal E, Silva H, Ortega L, Espinoza E, Martinez C. The acromion and its different forms. *Int J Morphol* 2010; 28(4): 1189-1192.
3. Coskun N, Karaali K, Cevikol C, Demirel BM, Sindel M. Anatomical basics and variations of the scapula in Turkish adults. *Saudi Med J* 2006; Vol 27(9): 1320-1325.
4. Bigliani LU, Morrison DS, April EW. The morphology of acromion and its relationship to rotator cuff tears. *Orthop. Trans* 1986; 10:228.
5. Edelson JG, Taitz C. Anatomy of the coraco-acromial arch. *J Bone Joint Surg (Br)* 1992; 74 -B: 589-94.
6. Musa A, Tuba S, Mahinur U, Ismail Z, Serpil A, Duran E. The morphometrical and morphological

- analysis of the acromion with Multidetector computerized tomography. *Biomedical Research* 2014; 25(3); 377-380.
7. DePalma AF, Brand RA. Origin and Comparative Anatomy of the Pectoral Limb. *Clin Orthop Relat Res.* v. 2008; 466(3).
  8. Sangiampong A, Chompoopong S, Sangvichien S, Thongtong P, Wongjittaporn S. The acromial morphology of Thais in relation to gender and age: Study in scapular dried bone. *J Med Assoc Thai* 2007; 90(3): 502-7.
  9. Saha S, Vasudeva N, Paul S, Gautam VK. Study of acromial morphology in Indian population. *Rev Arg de Anat Clin* 2011; 3(2): 84-88.
  10. Schetino LPL, Sousa Jr RR, Amâncio GPO, Schetino MAA, Almeida-Leite CM, Silva JH. Anatomical variations of acromions in Brazilian adult's scapulas. *J Morphol Sci* 2013; 30(2): 98-102.
  11. Paraskevas G, Traveas A, Papaziogas B, Kitsoulis P, Spanidou S. Morphological parameters of the acromion. *Folia morphol* 2008; 67(4): 255-260.
  12. Singh J, Puhuja K, Agarwal R. Morphometric parameters of the acromion process in adult human scapulae. *IJBAMR* 2013; vol 2(8): 1165-1170.
  13. Mansur DI, Khanal K, Haque MK, Sharma K. Morphometry of acromion process of scapulae and its clinical importance amongst Nepalese population. *Kathmandu Univ med J* 2012; 38(2): 33-36

**Conflict of Interest: None**

**Source of Funding Nil**