



Case Study

Approaches to Treat Palato Radicular Groove Based on its Anatomy: Series of 3 Cases

Palka Kaur Khanuja*, S C Narula, R K Sharma, Shikha Tewari

Dept of Periodontics and Oral Implantology; PGIDS: Post Graduate Institute of Dental Sciences, Rohtak, India

ARTICLE INFO

Received: 28 Oct 2015
Accepted: 12 Dec 2015

ABSTRACT

Palatoradicular groove is a developmental anomaly which is most often observed in maxillary lateral incisors. This case report describes the successful treatment palatoradicular grooves with varying depth and extent in three patients.

Keywords: Palato radicular groove, Odontoplasty, Glass ionomer cement

1. INTRODUCTION

A palato-radicular groove (PRG) is a developmental anomaly most often found on the lingual surface of the maxillary lateral incisors or central incisors, and is characterized by a depression or concavity.^{1, 2} It is a developmental malformation that forms as infoldings of the inner enamel epithelium and Hertwig's epithelial root sheath (HERS). PRG formation most likely represents an aborted attempt of tooth bud to form an additional root.³

Commonly used terminologies to designate this malformation include distolingual groove, radicular lingual groove or palatogingival groove. These developmental grooves are of particular interest to

Corresponding author *

Dr Palka Kaur Khanuja,
Dept of Periodontics and Oral Implantology
Post Graduate Institute of Dental Sciences,
Rohtak, Haryana, 124001, India.
Phn no: - 09810336050
Email: khanuja.palka@gmail.com

dentists. Owing to the fact that these grooves act as funnels; they contribute to plaque accumulation down till the base of groove which is mostly inaccessible or atleast difficult to access for both clinicians and patients. Depending upon the anatomy of the tooth and groove, patient's compliance, other contributing factors to plaque accumulation, local and systemic factors; the influence of the presence of this particular tooth anomaly can manifest in oral cavity from anywhere between intermittent to continuous phase of gingival inflammation to the formation of a severe localized periodontal lesion; many a times with concomitant endodontic involvement.⁴

The radicular grooves are broadly classified into three types depending on the severity: Type I, the groove is short (does not extend beyond the coronal third of the root); type II, the groove is long (extends beyond the coronal third of the root) but is shallow as well, corresponding to a normal or simple root canal; and type III, the groove is long (extends beyond the coronal third of the root) and deep, resembling a complex root canal system.⁵ This paper reports two cases of unilateral PRG and one case with bilateral PRG.

Case 1:

A 30-year old male patient was referred to the Department of Periodontics and Oral Implantology, Post Graduate Institute of Dental Sciences (PGIDS), Rohtak, Haryana, India with a chief complain of bleeding from gums in upper front teeth region since 4 months. Oral examination revealed fair oral hygiene with PRG on the mid – palatal aspect on the left lateral incisor (22) associated with 8 mm of periodontal pocket (Figure 1).

The etiology of the patient's chief complaint was explained to him. Initial periodontal therapy, consisting of scaling and root planning was carried out. The patient was instructed about proper oral hygiene measures. Though at two-week follow-up visit, little

reduction in the pocket depth was noted; to treat the situation periodontal flap surgery was planned (Figure 2). Patients consent was taken after explaining the procedure in detail. After administration of local anesthesia a full thickness flap was reflected. Thereafter through debridement was done. As groove was deep enough it was sealed with Glass ionomer cement and sutures were placed (Figure 3).

Case 2:

A 28-year old male patient was referred to the Department of Periodontics and Oral Implantology, PGIDS with the chief complaint of maligned maxillary left central incisor (21). Patient had fair enough oral hygiene. Tooth 21 was supra erupted with PRG on the mid – palatal aspect associated with 5mm of periodontal pocket and clinical attachment loss of 8 mm (Figure 4). Radiograph revealed vertical defect in association with 21. Two weeks after completion of phase 1 therapy, periodontal flap surgery was planned for the patient (Figure 5). As groove was shallow; through debridement followed by odontoplasty for PRG was carried out for the patient (Figure 6).

Case 3:

A 25- year old male patient reported to the Department of Periodontics and Oral Implantology, PGIDS with a chief complaint of bleeding from gums and increasing spacing between upper front teeth. Though the overall diagnosis for the patient was mild generalized periodontitis; maxillary right and left central incisors (11 and 21 respectively) in particular had severe attachment loss. On careful exploration, presences of PRG were recognized on mesial aspect of both right and left central incisors) with probing depth of 7mm on each (Figure 7). Such presentation of PRG is rare indeed. A month after through scaling and root planning; periodontal flap surgery was performed for the patient (Figure 8). As grooves were shallow,

recontouring of grooves with the bur served the purpose (odontoplasty).

As heat vitality test proved to be positive in all the cases; therefore no endodontic treatment was performed for any of the patients. All the patients were given postsurgical instructions and were kept on antibiotic-analgesic coverage (amoxicillin 500 mg TID for five days and ibuprofen 400 mg for three days). A chlorhexidine gluconate mouthwash (0.12 percent) was also advised to supplement oral hygiene regimen. The patients were recalled again one week later for suture removal and oral hygiene instructions were reinforced. Examination after two months revealed reduction in the pocket depth in all the cases and patients were satisfied with the results. Overall improvement in the oral hygiene was noted for all the patients.

2. DISCUSSION

Palato- radicular grooves are quite variable in their depth and also differ in the distance and direction traversed down the root.⁶ This report presents three cases of PRG with variations in the depth and extent of groove and thereby involving the attachment apparatus to varying extent.

The cases in the present report were treated with periodontal flap surgery intended to do through debridement. The groove was sealed with glass ionomer cement (GIC) in case 1 and selective recontouring via enameloplasty/ odontoplasty was carried out for cases 2 and 3.

We used GIC as a sealer as is known to have many advantages, including the ability to bond chemically to enamel and dentin, being biocompatible, good cavity sealing abilities, ease of use and unique antibacterial property.^{7,8}

Palatal grooves have predilection for maxillary lateral incisors. Occurrence on central incisors is less frequent.⁹ In the present documentation occurrence and

treatment of PRG on 3 central incisors and 1 lateral incisor is discussed.

The groove has likelihood for presence on the lateral surfaces (60 percent) than in the mid-palatal region (40 percent).¹⁰ However, some authors observed the presence of the groove more frequently on the midpalatal regions.¹¹ Some authors have postulated the presence of groove on the proximal surfaces to be more detrimental than a mid-palatal groove. It is believed that these sites serve as potential areas for plaque accumulation. Also it becomes comparatively difficult to clean proximal surfaces of teeth.

We came across PRG on the mid-palatal surface in case 1 and case 2. In case 3; PRG was observed on the bilaterally on the mesial surfaces of both the maxillary central incisors.^{12,13}

Depending on the severity of the periodontal defect and type of groove (deep or shallow) various treatment modalities have been suggested. In case of shallow grooves; curettage procedure with or without a flap accompanied by odontoplasty is suggested by some authors.¹⁴⁻¹⁵

It is also proposed that shallow grooves associated with only a shallow periodontal pocket should be preferably treated via closed curettage to prevent attachment loss. If an open flap curettage is done for such cases then loss of periodontal attachment rather than gain is expected to occur. When dealing with grooves associated with moderate probing depth, flap surgery along with sealing of the groove with a restorative material such as glass ionomer cement, dental amalgam, or a light-activated, resin based composite is advocated. The chief disadvantage of these procedures may be the formation of a long junctional epithelium instead of a true regeneration taking place to replace the lost attachment apparatus.

With regards to sealants it is proposed that when a sealant of some type is used, it is known to prevent the

formation of a dead space between the gingival flap and the depressed groove. In particular GIC is a material of choice owing to its antibacterial property and ability to provide a tight seal.

This case report presented the successful treatment of a series of cases with palatoradicular grooves. The key to achieving long-term favorable results in PRG is accurate diagnosis of the problem and eventual elimination of inflammatory irritants and contributory factors. Awareness on the part of clinician about existence of such a peculiarity may help to avoid misdiagnosis and improper treatment of these patients.

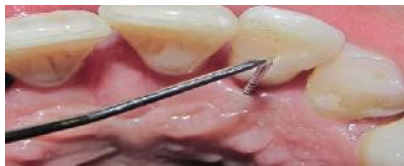

Fig 1: Figure shows palatoradicular groove (PRG) with respect to 22 with 8 mm of periodontal pocket (case 1).

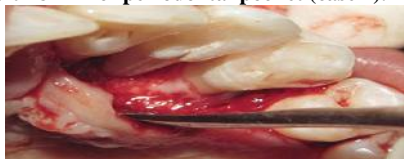

Fig 2: A full thickness mucoperiosteal flap revealing palatoradicular groove extending the full length of root (case 1).

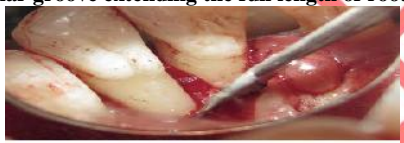

Fig 3: Glass ionomer cement was used to seal the groove as can be seen in the mirror (case 1).

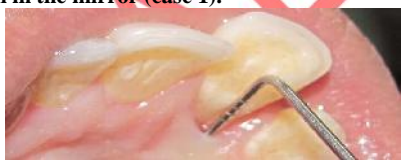

Fig 4: Figure shows supra erupted 21 with PRG on the mid – palatal aspect associated with 5mm of periodontal pocket (case2).

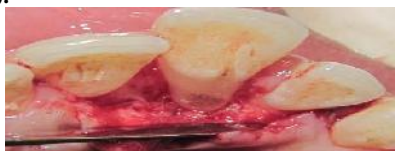

Fig 5: A full thickness mucoperiosteal flap revealing palatoradicular groove extending the full length of root associated with abundance of calculus and bone loss (case 2).

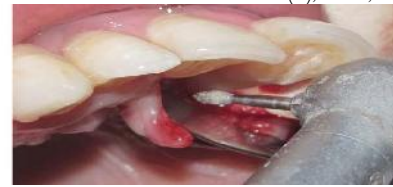

Fig 6: Odontoplasty was carried out for the patient after through debridement (case2).

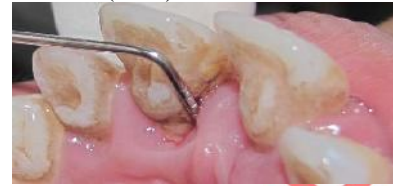

Fig 7: Figure shows palatoradicular groove on 11 associated with probing depth of 7mm in a patient having bilateral PRG (case 3).

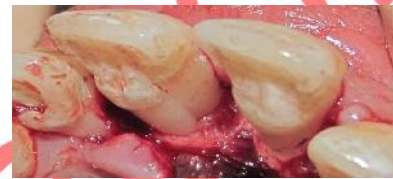


Fig 8: Palatoradicular groove on 11 of the same patient after flap reflection associated with bone loss (case 3).

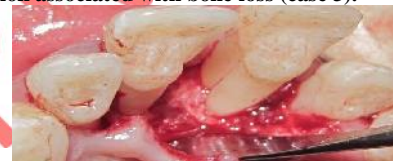

Fig 9: View after through debridement followed by odontoplasty (here 21 can be better appreciated).

3. References

1. Ennes JP, Lara VS. Comparative morphological analysis of the root developmental groove with the palato-gingival groove. *Oral Dis* 2004;10:378-382.
2. Walton RE, Torabinejad M. Principles and practice of endodontics. 3rd ed. Philadelphia: Saunders; 2002. p. 499.
3. Simon JH, Glick DH, Frank AL. Predictable endodontic and periodontic failures as a result of radicular anomalies. *Oral Surg Oral Med Oral Pathol.* 1971;31: 823–826.
4. Gound TG, Maze GI. Treatment options for the radicular lingual groove: a review and discussion. *Pract Periodontics Aesthet Dent.* 1998; 10(3):369-375.

5. Gu Y. A micro-computed tomographic analysis of maxillary lateral incisors with radicular grooves. *J Endod.* 2011;37:789-792.
6. Kogon SL. The prevalence, location and conformation of palato-radicular grooves in maxillary incisors. *J Periodontol.* 1986;57:231-234.
7. Tyas MJ. Milestones in adhesion: glassionomer cements. *J Adhes Dent.* 2003; 5(4):259-266.
8. Davidovich E, Weiss E, Fuks AB, Beyth N. Surface antibacterial properties of glass ionomer cements used in atraumatic restorative treatment. *J Am Dent Assoc.* 2007; 138(10):1347-1352.
9. Kogon SL. The prevalence, location and conformation of palato-radicular grooves in maxillary incisors. *J Periodontol.* 1986; 57(4):231-234.
10. Bacic M, Karakas Z, Kaic Z, Sutalo J. The association between palatal grooves in upper incisors and periodontal complications. *J Periodontol.* 1990; 61(3):197-199.
11. Kogon SL. The prevalence, location and conformation of palato-radicular grooves in maxillary incisors. *J Periodontol.* 1986; 57(4):231-234.
12. Hou GL, Tsai CC. Relationship between palato-radicular grooves and localized periodontitis. *J Clin Periodontol.* 1993; 20(9):678-682.
13. Bacic M, Karakas Z, Kaic Z, Sutalo J. The association between palatal grooves in upper incisors and periodontal complications. *J Periodontol.* 1990; 61(3):197-199.
14. Holem S. The radicular groove. *J Am Dent Assoc.* 1978; 97:441-444.
15. Ramirez JM. Management of a periodontal lesion associated with a lingual groove. *Oral Health* 1984; 74:23-25.
16. Rankow HJ, Krasner PR. Endodontic applications of guided tissue regeneration in endodontic surgery. *J Endod.* 1996; 22(1): 34-43.

Conflict of Interest: None

Source of Funding Nil