



## Short Communication

# Bilateral Transposition of Canine with Lateral Incisor in Mandibular Arch: A Rare Report of Unique Presentation

Sudheer Babu Chinthapatla<sup>1</sup>, Sreekanth Kumar Mallineni<sup>2,\*</sup>, Anil Kumar Patil<sup>3</sup>, Azher Mohiuddin Mohammad<sup>4</sup>

<sup>1</sup> Consultant orthodontist, Little teeth, The Children Dental Hospital, Nellore, AP, India.

<sup>2,3</sup> Consultant Paediatric Dentist, Little teeth, The Children Dental Hospital, Nellore, AP, India.

<sup>4</sup> Consultant Oral Maxillo-facial Surgeon, Little teeth, The Children Dental Hospital, Nellore, AP, India..

### ARTICLE INFO

### A B S T R A C T

Received: 05 Jun 2016  
Accepted: 21 Jun 2016

Transposition is the positional inter-change of two adjacent teeth, or eruption of a tooth in a position occupied normally by non-adjacent tooth. The transposition occurs commonly in the maxillary arch than the mandibular arch. The etiological factor of this condition includes retained deciduous tooth, migration of tooth bud and local trauma. However, the exact etiology of this anomaly has not been clearly stated in the published literature. The purpose of the present case report was to report a case of bilateral transposition of mandibular canines with lateral incisors.

**Keywords:** Transposition, mandibular, local trauma

## 1. INTRODUCTION

Tooth transposition is the development or eruption of a tooth occupied by adjacent tooth's position or positional interchanges of two adjacent teeth<sup>1</sup>. This phenomenon is prevalent in 0.4% of Indian population<sup>2</sup>. The best-documented single etiologic factor is the roots of retained primary cuspids that deflect the permanent canines, causes impactions and/or transpositions.<sup>3</sup> Transposition of tooth buds, migration of a tooth during eruption, heredity, and local trauma are some other possible etiological factors. Consequently, genetic influence on

### Corresponding author \*

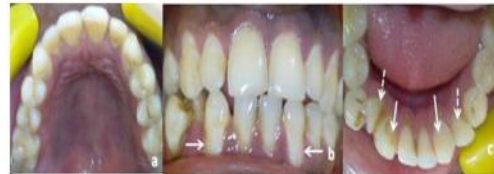Dr Sreekanth Kumar Mallineni  
Consultant Paediatric Dentistry  
Little teeth, The Children Dental Hospital  
Nellore, AP, India  
Email: drmallineni@gmail.com

SK Mallineni *et al* transpositions has also been reported.<sup>4,5</sup> There is no gender or racial influences on the transposition of canines in the mandibular arch.<sup>6</sup> Diagnosis of transposition consists of two main steps (i) Identification and (ii) Classification into complete or incomplete transposition. Incomplete transposition display crown displacement only, whereas complete transposition involves the whole tooth. Transposition occurs most commonly in the maxillary arch than the mandibular arch. Unilateral transposition is frequently seen than the bilateral transposition and left side is commonly seen than the right side. Among, all types of transpositions, maxillary canine – premolar transposition is the most frequent type. Transposition in the mandibular arch is very rare and transposition of canine with lateral incisors is not commonly cited. Therefore the purpose of the present short communication is to report a case of bilateral transposition of canines with lateral incisors in mandibular arch.

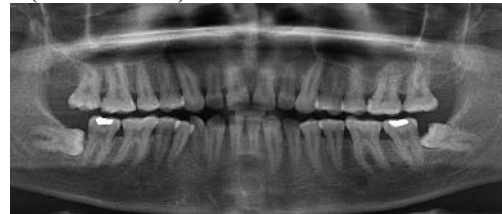
## 2. CASE REPORT

A 31-year-old patient visited to our clinic for regular dental check up. On clinical examination he has Angle's class I molar relation on both sides with crowding in the lower anterior region. Both the midlines were not coinciding with each other i.e the upper midline has been shifted to left side by 1mm and the lower midline has been shifted to right side by 1.5 mm. a clear cut tooth material-arch length discrepancy is present in lower arch with mild crowding in the anterior region. Bilateral complete transposition of mandibular canines with lateral incisors was observed on clinical examination [Fig.1] and confirmed with radiographic findings[Fig.2]. The proposed treatment plan was to align the teeth in transposed position as the teeth are completely transposed, with proximal slicing to create space for relieving crowding and careful reshaping the transposed teeth to improve appearance

and harmonize both the arches. The other alternative treatment plan was to move the transposed lateral incisor mesially and canine into its original position. After discussing all the possible treatment options with risks and benefits with the patient. The patient was not willing for any type of treatment procedures. Scaling and oral prophylaxis were performed and he was discharged from the clinic.



**Fig 1: Intra-oral views a) Maxillary arch 2) Frontal view (arrows) showing transposition of canines and c) Mandibular arch showing transposition of canines (arrows) with lateral incisors (dashed arrows).**



**Fig 2: Orthopantomogram showing bilateral transposition of canines with lateral incisors**

## 3. DISCUSSION

When teeth are transposed, their natural sequence in the arch is changed, leading to functional and esthetic problems.<sup>7</sup> Prevalence of canine with first premolar in maxillary arch is around 71% of all the reported cases, whilst the prevalence of mandibular transposition that affects canine and lateral incisor is of 0.03%.<sup>8</sup> If the anomaly is bilateral, the same teeth are affected on both sides; whereas asymmetrical transposition is rare. Transposition has never been reported in deciduous dentition.<sup>8</sup> Many theories have been proposed to explain the etiology of transposition includes, altered eruption paths, positional interchange of tooth buds presence of retained primary teeth and trauma. In the present case mandibular canines are transposed with mandibular lateral incisors, which is a very rare and unique presentation. Shapira reported that in mandibular arch

transposition of canines could be developed due to distally directed eruption of permanent lateral incisor which leads to premature loss of primary canine.<sup>3</sup> Three treatment options were given to the patient were include, to leave the dentition as it is.

To mimic the transposed canines into lateral incisors and transposed lateral incisors into canines and simulate the ideal dentition that includes relatively simple mechanics and lesser treatment duration. It has a several esthetic and functional concerns especially the canine guided occlusion will be lost and gingival contour is altered in the anterior region which requires an additional periodontal recontouring procedures,<sup>7</sup> and to correct the transposed canine into it's original position by fixed orthodontic treatment modality. Which depends on various factors such as the patient's degree of occlusion, dental crowding, esthetics, the position of the radicular apices, socio-economic factors, and the last but the major factor is patient's motivation.<sup>9,10</sup> In the present case, transposition is diagnosed as complete type with the help of clinical examination and radiographic findings. So, initially the lateral incisor has to be moved lingually to remove interference for the canine, and canine should be moved distally with orthodontic mechanics and after reversing the transposed teeth, the achieved treatment results will fulfill all the functional and esthetic considerations and maintain a stable occlusion.

#### 4. CONCLUSION

The clinician should be aware of morphology of teeth to identify the transposition anomaly in the patients. This is a unique and rare presentation of transposed canines with lateral incisors in mandibular arch.

#### 5. REFERENCES

1. Peck L, Peck S, Attia Y. Maxillary canine-first premolar transposition, associated dental anomalies and genetic basis. *Angle Orthod.* 1993; 63: 99-109;

2. Papadopoulos MA, Chatzoudi M, Kaklamanos EG. Prevalence of tooth transposition A Meta-Analysis. *Angle Orthod.* 2010;80:275-85.
3. Shapira Y. Transposition of canines. *J Am Dent Assoc* 1980; 100: 710-2.
4. Chattopadhyay A, Srinivas K. Transposition of teeth and genetic etiology. *Angle Orthod.* 1996; 66: 147-52;
5. Nicola JE, Sherriff M, Cobourne MT. Dental transposition as a disorder of genetic origin. *Eur J of Orthod* 2006; 28: 145-51;
6. Yılmaz HH, TurkkahramanH, Sayın MO. Prevalence of tooth transpositions and associated dental anomalies in a Turkish population. *Dentomaxillofacial Radiology.* 2005; 34: 32-5;
7. Kuroda S, Kuroda Y. Non extraction treatment of upper Canine-premolar transposition in an adult patient *AngleOrthod.* 2005; 75: 472-7.
8. Potrubacz MI, Tepedino M, Chimenti C. Maxillary canine-first premolar bilateral transposition in a class III patient: A case report. *Angle Orthod.* 2016; 86: 509-9.
9. Filho LC, Cardoso MA, Tien Li An, Bertoz FA. Maxillary canine-first premolar transposition restoring normal tooth order with segmented mechanics. *Angle Orthod.* 2007; 77: 169-75.
10. Teresa DM, Stefano M, Annalis M, Enrico M, Vincenzo C, Giuseppe M. Orthodontic treatment of the transposition of a maxillary canine and a first premolar: A case report. *J of Med Case Reports.* 2015; 9: 4.

**Conflict of Interest: None**

**Source of Funding: Nil**