



Original Article

Reproductive Toxicity of Copper Nanoparticles in Male Albino Rats

Tara chand kalirawana¹, Priyanka Sharma¹, S C Joshi^{1,*}

Reproductive Toxicology Unit, Department of Zoology, University of Rajasthan, Jaipur 302004, India

ARTICLE INFO

A B S T R A C T

Received: 01 Feb 2018
Accepted: 25 Feb 2018

Objective: Recent studies have reported that metallic nanoparticles and ions from Copper nanoparticles had potential adverse effects. However, the biological effects of Copper nanoparticles on male reproductive function remain unclear. The objective of this study was to investigate the reproductive toxicity in adult male rats following oral administration of Copper nanoparticles. **Methodology:** Poly vinylpyrrolidone coated Copper nanoparticles of average particles size 60 and 40 nm were used to analyze reproductive toxicity. Male Wistar rats were divided into five groups of six animals each. The control group received only the vehicle (distilled water) whereas animals in Groups II, III, IV, and V received Cu NPs dissolved in distilled water orally at the dose level of 1 and 2 mg/kg b wt/day, respectively of each size for 45 days. The effects on male reproductive function were observed, including testicular to body weight, the epididymal sperm parameters. The level of male sex hormones in serum and protein, glycogen, sialic acid, and cholesterol were evaluated in the testes. **Results:** The result showed a significant decline in sperm density and motility in treated rats. A decrease in sex hormones levels was observed in all the treated groups. Post fertility test showed 40%, 50%, 60%, and 70% negative results. In biochemical parameters, testicular protein and cholesterol level were significantly improved while the glycogen and the sialic acid content decreased significantly. **Conclusion:** Copper NP exposure not only altered the hormonal and biochemical structure but also reduced male fertility in adult Wistar rats.

Keywords: Nanoparticle, reproductive toxicity, testis, sperm density.

1. INTRODUCTION

Nanotechnology is a relatively new science; however, it already has numerous applications in routine life, ranging from consumer goods to medicine. Despite the wide applications of nanomaterials, there has been a great lack of evidence about the impact of nanoparticles (NP) on human health and the environment. The key parameters that

Corresponding author *
Prof. S. C. Joshi,
Department of Zoology,
University of Rajasthan,
Jaipur 302004, India
Email: s_c_joshi2003@rediffmail.com

influence its toxicity are the chemical nature, the particle size, the morphology and the chemistry of the surface.

Nano-sized copper particles, one of the fabricated metal nanoparticles, are now produced industrially and are commercially available. Recently, copper nanoparticles are used as an additive in lubricants, metallic coatings, polymers, and inks, etc. Due to the excellent repair effects of nano-copper particles, to effectively reduce friction and wear, or to repair a worn surface, they are added to lubricating oil as an additive.¹The nano-copper particles are invariably deposited on the graphite surface to expressively develop the charge-discharge property, such as Coulomb efficiency, cycle characteristics and high performance as the anode material for lithium-ion batteries.²

The field of nanotoxicology still lacks the information and clarification necessary to achieve a true risk assessment.³ Nowadays, due to the extensive application of nanoparticles, there is growing concern about the effects of these substances, such as reactive oxygen (ROS) on human health and the environment.⁴It is likely that nano-copper particles, similar to other nanomaterials, enter the environment and the human body through different routes, such as effluents, consumer products, and disposal, spills during shipping and treatment. If the ingestion of copper exceeds the range of human tolerance, it would cause toxic effects such as hemolysis, jaundice and even death. More recently, the study specifies that common copper surplus in vivo can prompt a set of toxicological activities such as hepatocirrosis⁵, changes in lipid profile, renal dysfunction, oxidative stress⁶ and the stimulus of the mucous membrane of the digestive tract, etc. The nanoparticles can cross the cell membrane without effort and even cross the blood-brain barrier and the blood testicles barrier, so it can affect the whole body.^{7, 8}

The toxicity of nanoparticles and other cellular responses depends on the nature of the material and doses have been used. This evidenced that liver parenchyma cells have a major role in the elimination of nanoparticles from the blood.⁹Theoretically, nanoparticles can have some negative consequence on human health and the environment and their apparent impact on male reproductive function has not yet been clarified.

In addition, it is known that oxidative stress is one of the foremost mechanisms of this deterioration. However, the effects of the copper nanoparticle on the male spermatogenic process remain indistinct. This study investigates the effects of different doses of copper nanoparticles at a hormonal and biochemical level in male albino rats.

2. MATERIALS AND METHODS

Copper nanoparticles

Copper nanoparticles coated with PVP from APS 60 and 40 nm were purchased from Nano beach Company, G-25, East Gokalpur, Delhi, India. The Cu NPs were suspended directly in deionized water (distilled water) and dispersed by ultrasonic vibration for 20 minutes to produce two different

concentrations at 1 and 2 mg/kg for each size of 40 and 60 nm. The Cu NP suspension was vortexed before it was orally administered.

Experimental model

The present study was carried out on male albino rats (*Rattusnorvegicus*) of the Wistar strain weighing from 150 to 200 g. The animals were accommodated in a well-ventilated and hygienic room with natural light and dark cycle (12 hrdark/clear) with arelative humidity of 55% and room temperature of 25 ± 2 °C. They were housed individually in clean polypropylene cages with bedding of sawdust and covers with stainless steel wire covers. The rats were fed standard pelleted feed obtained from Ashirwad Food Industries Ltd., Chandigarh (Punjab) and fresh water were supplied *ad libitum* during the course of the study. The guidelines for care and use of animals for scientific research (INSA) were strictly followed throughout the course of the investigation.¹⁰Before starting the experiment the male rats were kept with normal oestrous females for mating.

Experimental design

Wistar male rats were separated into five groups of six animals each.

G I- Control received vehicle (Distilled water) only

G II- Animals received 1 mg/kg bwt/day of 40 nm Cu NPs orally for 45 days

G III- Animals received 2 mg/kg bwt/day of 40 nm Cu NPs orally for 45 days

G IV- Animals received 1 mg/kg bwt/day of 60 nm Cu NPs orally for 45 days

G V- Animals received 2 mg/kg bwt/day of 60 nm Cu NPs orally for 45 days

Autopsy schedule

At the end of the experiment, the rats were weighed and sacrificed under anesthesia with light ether. The blood was collected by cardiac puncture. The male reproductive organs were dissected, washed with distilled water, dried, weighed and managed for sperm dynamics and biochemical studies.

Parameters studied

Body and reproductive organs weight

The initial body weight was taken on the first day of treatment and the final body weight of each animal was documented after the last day of treatment. The treated animals were sacrificed along with the controls. Blood (2 ml) was collected in sterile tubes by cardiac puncture for blood studies and allowed to clot. In addition, the coagulated blood was centrifuged to isolate the serum for serological studies. At autopsy, the reproductive organs (testicles, epididymis, seminal vesicle, prostate and vas deferens) excised from the surrounding tissue and were transferred free of blood for weighing.

Fertility test

The mating exposure test of all animals was performed. They were cohabitating with normal proestrus females in a 1: 3 ratio. The vaginal plug and the presence of sperm in the

vaginal smear were checked for positive coupling. The females were separated and pregnancies were observed when the mothers gave birth.¹¹

Sperm dynamics

Sperm motility was determined in the cauda epididymis.¹²The epididymis was removed immediately after anesthesia. The known weight of epididymis was gently teased in a specific volume of physiological saline (0.9% NaCl) to release the spermatozoa from the tubules and placed on the slide of the Neubauer chamber. The sperm suspension was examined within five minutes after its isolation from the epididymis. The results were determined by counting the motile and immobile spermatozoa in at least ten separate and randomly selected fields. The results were finally expressed as a percentage of motility.

The sperm density was calculated in the testes and the epididymis in millions/ml as per dilution according to the method of Prasad et al., 1972.¹²Total number of sperms were counted using haemocytometer after further diluting the sperm suspension from testis.

Biochemical test

Total protein,¹³ glycogen,¹⁴ sialic acid¹⁵ and cholesterol¹⁶ were evaluated in the testes.

Hormone analysis

The serum levels of testosterone, Follicle stimulating hormone (FSH) and Leutinizing hormone (LH) of the treated and control groups were estimated by radioimmunoassay (RIA) to observe the changes in the gonadal hormone.¹⁷ Serum obtained by centrifugation at 3000 rpm and stored at -20 °C for determination of hormones.

Statistical analysis

The data obtained from the experiments were presented as mean \pm SE and analyzed statistically by the use of Single factor ANOVA and the significance of the differences were set at P 0.05 (significant) and p 0.01 (highly significant) levels.

3. RESULTS & DISCUSSION

The study revealed a non significant decrease in body weight after administration of copper NP at a dose level of 1 and 2 mg/kg / b. wt / day in relation to the control group (Table 1). But the significant decrease (p 0.01) in the weight of the testes attributable to the loss of germ cells and elongated spermatids.¹⁸It has been reported that reduced levels of testosterone propionate cause adiminution in body mass index.¹⁹ Similarly, the weight of the testes, epididymis, prostate and seminal vesicles in the treated group was also significantly (p 0.05) decreased (Table 1).

Copper NP reduced the spermatogenic potential by reducing the number of sertoli cells since the weight of the testicles depends to a large extent on the mass of differentiated spermatogenic cells²⁰ or it could be due to a decrease in the production of seminiferous tubular fluid, which contributes to the weight of the testicles.²¹ The decreased weight of the testes in the treated rats clearly indicated that the copper NPs

caused a structural and functional change in the reproductive organs that could be due to the inequality of the reproductive hormones. Similarly, the decrease in the weight of the accessory sex organs could be due to the low accessibility of androgens or the antiandrogenic activity of the nanoparticles.²²

A severe alteration in sperm motility was observed in the cauda epididymis and the spermatic density in the testes decreased in a non-significant way and in the epididymis it decreased significantly (p 0.05) after the administration of copper nanoparticles compared to the control (Table 2).

A significant decrease (p 0.05) in the motility and density of the caudal epididymal sperm suggested an insufficient supply of testosterone to the epididymis, possibly causing an alteration of epididymal function since it is known that the structure and function of the epididymis depend on the androgens. The copper nanoparticle affects nerve impulses by reducing the acetylcholinesterase activity that leads to the suppression of gonadotrophic hormones (LH and FSH). Clampdown of gonadotrophins might be decreased sperm density in testes.²³ Decreased sperm density in the epididymis is an indicator of reduced spermatogenesis as a result of the toxicity of any agent. Low caudal epididymal sperm density in our study may be due to alteration in androgen metabolism. The physiological and biochemical integrity of epididymis are dependent on androgens.²⁴

The control rats showed a 100% fertility rate by mating exposure test. Rats administered with copper nanoparticles at doses of 1 and 2 mg/kg/b.wt/day-1 revealed 60 and 70% negative fertility with the 40 nm copper NP and 40 and 50% of negative fertility with 60 nm copper NP treated rats as compared to the control group (Table 2). A decrease in fertility aptitudes in treated rats has been recognized as an impediment to motility and viability of sperm. 70% infertility in rats could be attributed to the lack of progressive progression and reduction of sperm density and the altered biochemical environment of the epididymal tail.²⁵

In biochemical parameters, testicular protein and cholesterol level were significantly improved (p 0.05) after administration of copper nanoparticles in rats. The glycogen level in the testes decreased significantly (p 0.01) in the rats treated with copper NP and the sialic acid content decreased significantly (Table 3). Protein biosynthesis is a crucial factor for testicular development and spermatogenesis. A high level of total protein content generally specifies hepatic detoxification, which produces inhibitory effects on the activities of the enzymes involved in the biotransformation of androgens.²⁶ These effects may be responsible for the inhibition of spermatogenesis. The increase in cholesterol level may be due to the decrease in androgen production, which causes an accumulation of cholesterol in the testes and, therefore, alters spermatogenesis.²⁷

A drop in the level of glycogen reveals a decrease in the number of postmeiotic germ cells that are supposed to be the sites of glucose metabolism.²⁸ The inhibition of glycogen

synthesis can affect the sperm maturation process and, finally, decreased the spermatogenesis process. The structural integrity of the acrosomal membrane depends on the sialic acid; the reduced content of sialic acid could modify the structural integrity of the acrosomal membrane, eventually affecting the metabolism, motility, and sperm fertilization capacity.²⁹

The results of this experimental study indicated that copper nanoparticles in professed concentrations have a different effect on sex hormones and serum cholesterol. The pituitary hormones (LH and FSH) that have protein structure diminished by the injection of nanoparticles and this reduction was more significant for FSH (Figure-1). The nanoparticles can inhibit the function of the endocrine system by blocking the pituitary-hypothalamus axis and is perhaps due to the reduction in the level of Gn RH. Subsequently, FSH and LH are pituitary hormones, therefore, this decrease can be measured as a result of the penetration of nanoparticles from the blood-brain barrier.⁸ Testosterone is the foremost androgen of the testes and is essential for sperm production and maintenance of accessory sex organs.³⁰ The level of testosterone, FSH and LH decreased significantly (P <0.01) after treatment with copper NP (Figure-2 and 3). A reduced serum testosterone validated the inhibitory effects of copper NP on the secretion of pituitary gonadotropins (FSH and LH) and, in turn, on testosterone biosynthesis. A low level of testosterone halts spermatogenesis.³¹ The hormonal alterations produced by NP favor the direct toxic effect of the nanoparticle or possibly through a change in the neuroendocrine environment that results in the inhibition of the pituitary-gonadal helix.³² The disposition of androgens not only suppresses spermatogenesis, which leads to a low concentration of sperm but also alters the epididymal environment, which makes it hostile for physiological maturation and sperm survival. In conclusion, exposure to copper NP not only altered the hormonal and biochemical structure but also reduced male fertility in Wistar rats.

The statistical analysis of our results revealed that the concentration of the hormone testosterone in the rats treated with Cu NP decreased significantly in comparison of the control groups (P <0.001)(Figure-3). This could be caused by the opposite effects of the nanoparticles in the Leydig cells, resulting in a reduction in the production of hormones. The nanoparticles can decrease and disrupt the secretion in the cells by the disturbing effect on the mitochondria. Nanoparticles also increase the release of reactive oxygen molecules, such as superoxidase and amplified protein oxidation, which causes cell death, therefore, the testosterone generating cells are reduced.³³ Another hypothesis is the decrease in the acute steroidogenic regulatory StAR gene expression due to the exposure of nanoparticles caused the synthesis of reduced testosterone. The product of this gene is a transport protein that transports

cholesterol to the inner cell membrane of the mitochondria for the production of steroid hormones.³⁴

The analysis of FSH and testosterone in male rat revealed that the levels of FSH and testosterone were significantly reduced with the treatment with Cu NPs. The results suggest that the reduction in testosterone level, which results from testicular damage, affected testicular spermatogenesis. Testicular damage was affected by reduced FSH.³⁴ The change of hormone reproductive levels indicates the abnormal reproductive axis function.³⁵

Table 1: Body and Organ weight (Effect of Cu NP for 45 days)

Treatment	Body weight		Testes	Epididymis	Vas deferens	Seminal vesical	Ventral prostate
	Initial	Final					
	g		mg/100g body wt.				
Group I (Water only)	182.43 ±1.29	187.14 ±2.02	1241.74 ±12.65	484.28 ±12.07	152.76 ±5.20	458.79 ±17.26	190.29 ±7.83
Group II	173.15 ±1.77	167.18 ^{ns} ±0.72	1097.70* ±17.57	429.85 ^{ns} ±23.55	135.66 ^{ns} ±10.06	390.51* ±10.87	152.10* ±11.50
Group III	181.83 ±3.56	172.20 ^{ns} ±1.88	1022.39* ±27.60	407.44* ±25.47	128.21* ±5.14	357.73* ±13.78	139.94* ±11.89
Group IV	175.69 ±1.76	169.62 ^{ns} ±2.31	1132.13* ±16.46	442.48 ^{ns} ±26.63	146.83 ^{ns} ±4.82	412.91* ±15.31	161.91 ^{ns} ±11.26
Group V	184.27 ±1.75	181.51 ^{ns} ±1.94	1089.20* ±21.63	432.24 ^{ns} ±20.23	138.71 ^{ns} ±4.03	391.26* ±8.67	148.25* ±14.62

(Mean ± SEM of 6 animals), (All groups compared with Group I), * = significant (P<0.05), ns = non-significant, ** = highly significant (P<0.01)

Table 2: Sperm Dynamics and Fertility (Effect of Cu NP for 45 days)

Treatment	Sperm motility (%)	Sperm density (million/ml)		Fertility (%)
	Cuda Epididymis	Testes	Cauda Epididymis	
Group I (Water only)	69.18 ±2.09	4.21 ±0.23	20.97 ±1.19	100 (+ve)
Group II	56.90* ±2.57	3.75 ^{ns} ±0.12	15.05** ±0.85	60 (-ve)
Group III	54.91* ±2.76	3.42* ±0.25	13.87** ±0.98	70 (-ve)
Group IV	57.51* ±2.78	3.92 ^{ns} ±0.22	17.84* ±1.20	40 (-ve)
Group V	55.44* ±3.11	3.69 ^{ns} ±0.19	15.01** ±1.02	50 (-ve)

(Mean±SEM of 6 animals), (All groups compared with Group I), * = significant (P<0.05), ns = non-significant, ** = highly significant (P<0.01)

Table 3: Tissue Biochemistry in testes(Effect of Cu NP for 45 days)

Treatment	Protein	Cholesterol	Glycogen	Sialic acid
	(mg/g)			
Group I (Water only)	249.90 ±4.04	5.47 ±0.39	2.86 ±0.2	5.69 ±0.33
Group II	277.40 ^{ns} ±4.27	6.02* ±0.43	2.17** ±0.17	4.90 ^{ns} ±0.20
Group III	279.40* ±3.88	6.50** ±0.48	1.88** ±0.13	4.47* ±0.33
Group IV	257.61 ^{ns} ±4.17	5.93 ^{ns} ±0.5	2.38** ±0.18	5.17 ^{ns} ±0.26
Group V	261.80 ^{ns} ±4.34	6.32* ±0.38	2.26** ±0.14	4.91 ^{ns} ±0.22

(Mean±SEM of 6 animals), (All groups compared with Group I), * = significant (P<0.05), ns = non-significant, ** = highly significant (P<0.01)

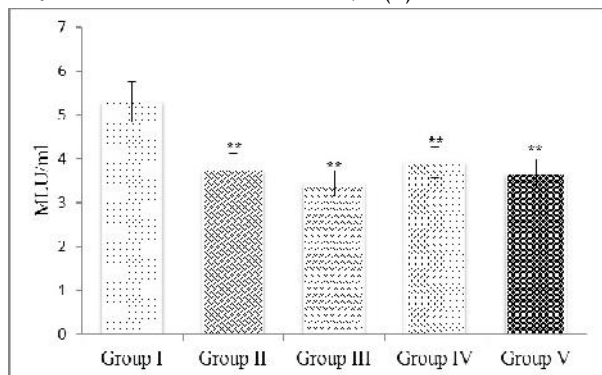


Fig 1: Follicle Stimulating Hormone (FSH) analysis in the serum of male rats after oral administration of copper nanoparticles for 45 days
Data are Mean ± SEM of 6 animals. All groups compared with Group I, * = significant (P<0.05), ns = non-significant, ** = highly significant (P<0.01).

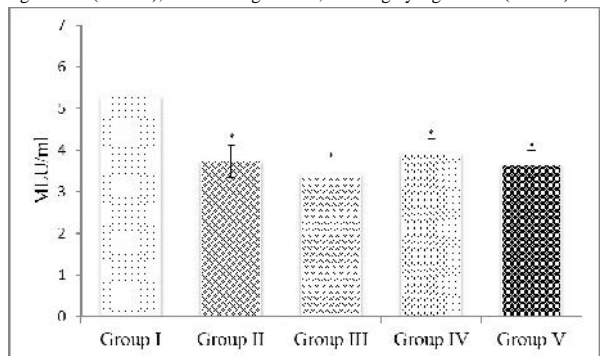


Fig 2: Leutinizing Hormone (LH) analysis in the serum of male rats after oral administration of copper nanoparticles for 45 days.
Data are Mean ± SEM of 6 animals. All groups compared with Group I, * = significant (P<0.05), ns = non-significant, ** = highly significant (P<0.01).

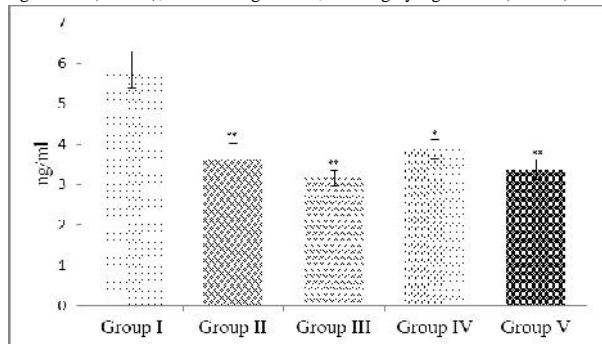


Fig 3: Testosterone analysis in the serum of male rats after oral administration of copper nanoparticles for 45 days.
Data are Mean ± SEM of 6 animals. All groups compared with Group I, * = significant (P<0.05), ns = non-significant, ** = highly significant (P<0.01).

4. CONCLUSION

In summary, the findings of this study indicate that copper nanoparticles can be considered as a reproductive toxicant. In addition, the toxicity observed in the reproductive toxicity studies to the male rats were different, in both the severity of the size and the concentrations at which those effects occurred, compared to control. The toxicity of copper nanoparticles was more severe in reproductive toxicity studies due to the change of physiochemical properties with size. The results of this study will be helpful to further study the long-term effects induced by copper nanoparticles and the scientific basis for setting standards for safety evaluation

for metallic copper nanoparticles. Further research is needed to elucidate exposure in human populations and mechanism of actions.

5. ACKNOWLEDGEMENT

This work was financially supported by the CSIR- UGC Junior research fellowship program (F. No.-F 41-4/NET/RES/JRF 1305/9960) to the first author. The authors have no other relevant affiliations or financial involvement with any organization or entity with the subject matter or materials discussed in the manuscript apart from those disclosed.

6. REFERENCES

- Liu G, Li X, Qin B, Xing D, Guo D, Fan D. Investigation of the mending effect and mechanism of copper nanoparticles on a tribologically stressed surface. *Tribol. Lett* 2004; 17: 961-966.
- Guo K, Pan Q, Wang L, Fang S. Nano-scale copper-coated graphite as anode material for lithium-ion batteries. *J Appl Elecchem* 2002; 32: 679-685.
- Johnston HJ, Hutchison G, Christensen FM, Peters, Han kin S, Stone V. A review of the in vivo and in vitro toxicity of and gold particulates, particle attributes and biological mechanisms responsible for the observed toxicity. *Crit Rev Toxicol* 2010; 40: 328-346.
- Yoshida Y, Itoh N, Saito Y, Hayakawa M, Niki E. Application of water-soluble radical initiator, 2,2'-azobis[2-(2-imidazolin-2-yl)propane] dihydrochloride, to a study of oxidative stress. *Free Radic Res* 2004; 38: 375-384.
- Bjorn, PZ, Hermann L, Max S, Heide KG, Barbara and Hartmut D. Epidemiological investigation on chronic copper toxicity to children exposed via the public drinking water supply. *Sci Total Environ* 2003; 302: 127-144.
- Gallhardi CM, Diniz, YS, Faine LA, Rodrigues HG. Toxicity of copper intake: Lipid profile, oxidative stress and susceptibility to renal dysfunction. *Food Chem Toxicol* 2004; 42: 2053-2060.
- Brandt D, Park B, Hoang M, Jacobe HT. Argyria secondary to ingestion of homemade silver solution. *Am Acad Dermatol* 2005; 53: 105-107.
- McAuliffe ME, Perry MG. Are nanoparticles potential male reproductive toxicant? A literature review. *Nanotoxicol* 2007; 1: 204-210.
- Heinlaan M, Ivask A, Blinova I, Dubourguier HC, Kahru A. Toxicity of nanosized and bulk ZnO, CuO and TiO₂ to bacteria *Vibrio fischeri* and crustaceans *Daphnia magna* and *Thamnocephalus platyurus*. *Chemosphere* 2008; 71: 1308-1316.
- Indian National Science Academy (INSA) (2000): Guidelines for care and use of animals in scientific

- research reported by Indian National Science Academy, New Delhi.
11. Ratnasooriya WD, Dharmasiri MG. Effects of *Terminalia catappa* seeds on sexual behaviour and fertility of male rats. *Asian J Androl* 2000; 2: 213-19.
 12. Prasad MRN, Chinoy NJ, Kadam KM. Changes in succinate dehydrogenase levels in the rat epididymis under normal and altered physiologic conditions. *FertilSteril* 1972; 23: 186-190.
 13. Lowry OH, Rosenbrough NJ, Farr AL, Randall RJ. Protein measurement with the Folin Phenol Reagent. *J BiolChem* 1951; 193: 265-75.
 14. Montgomery R. Determination of glycogen. *Arch BiochemBiophys* 1957; 67: 378-81.
 15. Warren L. Thethiobarbituric acid assay of Sialic acid. *J BiolChem* 1959; 234: 1971-75.
 16. Zlatkis A, Zak B, Boyle AJ. A new method for the direct determination of serum cholesterol. *J Lab Clin Med* 1953; 41: 486-92.
 17. Belanger A, Labrie F, Lemay A, Caron S, Raynaud JP. Inhibitory effects of a single intranasal administration of D-Ser (TBU) 6- Des-GlylONHz-LH-RH ethylamide agonist serum steroid levels in normal adult men. *J Steroid Bio chem.* 1980; 13:123-126.
 18. D'souza UJA, Narayana K. Induction of seminiferous tubular atrophy by a single dose of 5-fluorouracil (5-fu) in Wistar rats. *Indian J PhysiolPharmacol* 2001; 45: 87-94.
 19. MacDonald AA, Herbison GP, Showell M, Farquhar CM. The impact of body mass index on semen parameters and reproductive hormones in human males: a systematic review with meta-analysis. *Hum Reprod* 2010; 16: 293-311.
 20. Anway MD, Leathers C, Skinner MK. Endocrine disruptor vinclozolin induced epigenetic trans generational adult-onset disease. *Endocrinol*, 2006; 147: 5515-23.
 21. Sujatha R, Chitra KC, Latchoumycandane C, Mathur PP. Effect of lindane on testicular antioxidant system and steroidogenic enzymes in adult rats. *Asian J Androl* 2001; 3: 135-38.
 22. Jana K, Jana S, Samanta PK. Effect of chronic exposure to sodium arsenate on hypothalamic-pituitary-testicular activities in adult rats: possible an estrogenic mode of action. *Reproductive Biol Endocrinol* 2006; 4: 4-9.
 23. Robaire B, Seenundun S, Hamzeh M, Lamour SA. Androgenic regulation of novel genes in the epididymis. *Asian J Androl* 2007; 9: 545-553.
 24. Ouriquea GM, Tanise S, Etiane, MH, Isabela A, Finamora, Werner G, Glanznerb, Baldisserottoa B, Maria A, Pavanatoa, Paulo BD, Goncalvesb, Katia P, Barretoa. Resveratrol prevents oxidative damage and loss of sperm motility induced by long-term treatment with valproic acid in Wistar rats. *ExpToxicolPathol* 2016; 68: 435-443.
 25. Nwanjo HU, Iroagba IN, Nnatuanya IN, Eze, NA. Antifertility activity of dihydroartemisinin in male albino rats. *Int J Endocrinol* 2007; 13:14-19.
 26. Venkataramana, GV, Sandhya, Rani, PN, Murthy, PS. Impact of malathion on the biochemical parameters of gobiid fish, *Glossogobius giuris* (Ham). *J Environ Biol* 2006; 27: 119-22.
 27. Ngoula F, Watcho P, Dongmo M, Kenfack A, Kamtchouing P, Tchoumboue, J. Effects of pirimiphos-methyl (an organophosphate insecticide) on the fertility of adult male rats. *African Health Sci* 2007; 7(1): 3-9.
 28. Verma RS, Srivastva N. Effect of chlorpyrifos on thiobarbituric acid reactive substances scavenging enzyme and glutathione in Rat tissues. *Indian J Biochem Biophysics* 2003; 40: 423-28.
 29. Muroso EP, Derk RC, Akgul Y. In vivo exposure of young male rats to methoxychlor reduces serum testosterone levels and ex vivo Leydig cell testosterone formation and cholesterol side-chain cleavage activity. *ReprodToxicol* 2006; 21: 148-53.
 30. McLachlan RI, Donnell L, Meachem SJ, Stanton PG, De Kretser DM, Pratis K, Robertson, D.M. Identification of specific sites of hormonal regulation in spermatogenesis in rats, monkeys, and man. *Recent ProgHorm Res* 2002; 57: 149-79.
 31. Kavlock R, Cummings A. Mode of action: inhibition of androgen receptor function-vinclozolin-induced malformations in reproductive development. *Critc Rev Toxicol* 2005; 35: 721-726.
 32. Fartkhoni F M, Noori A, Momayez M, Sadeghi L, Shirani K, Babadi VY. The effects of nano titanium dioxide (TiO₂) in spermatogenesis in wistar rat. *Euro J Exp Bio* 2013; 3:145-149.
 33. Carlson C, Hussain SM, Schrand AM, Braydich-Stolle LK, Hess KL, Kong L, Tang M, Zhang T, Wang D, Hu K, Lu W, Wei C, Liang G, Pu Y. Nickel Nanoparticles Exposure and Reproductive Toxicity in Healthy Adult Rats. *Int J MolSci* 2014; 15: 21253-21269.
 34. Xiong X, Zhong A, Xu H. Effect of cyanotoxins on the hypothalamic-pituitary-gonadal axis in male adult mouse. *PLoS One* 2014; 9: e106585.

Conflict of Interest: None

Source of Funding: CSIR-UGC, New Delhi, India