



Case Study

Solitary Duodenal Somatostatinoma - Glandular Endocrine Tumour – A Case Study

Pramila R^{1,*}, Sridharan K², Akila R¹

¹Department of Pathology, Medical College Hospital & Research Centre (SRM Group), Tiruchirapalli, India [Affiliated to The Tamilnadu Dr. M.G.R. Medical University, Chennai]

²Department of Gastroenterology, Medical College Hospital & Research Centre (SRM Group), Tiruchirapalli, India [Affiliated to The Tamilnadu Dr. M.G.R. Medical University, Chennai]

ARTICLE INFO

A B S T R A C T

Received: 11 Dec 2017
Accepted: 10 Jan 2018

Somatostatinomas are rare carcinoid tumours that are observed in pancreas and duodenum, are seldom associated with typical clinical symptoms diagnosed by histological and immuno histochemical studies. A 67 year old male presented with dyspepsia – Endoscopy shows small sessile ulcerated polyp 1.5cm in size. The second part of the duodenal (Du2) biopsy is taken histopathological and immune histochemical studies carried out and reported as solitary duodenal stomatastationama - glandular endocrine tumor of second part of duodenum. Abdominal computed tomography showed a neuroendocrine tumour and polyps in the 2nd and 3rd part of the duodenum. Endoscopy revealed erosive gastritis with duodenal polyp with summit ulcer and suspected to gastrointestinal stromal tumour. Further biopsy confirmed the malignancy.

Keywords: Somatostatinoma, glandular endocrine tumour, Endoscopy, CT, histopathology

1. INTRODUCTION

Duodenal stomatastationama is a rare functioning neoplasma usually originated in the pancreas and duodenum¹. Based on the major hormone secreted, the functional neuroendocrine tumors have been classified according into insulinoma, gastrinoma, VIPoma, glucagonoma, and somatostatinoma². The first described by Larsson and Associates in the pancreas as a D cell tumor in pancreas in 1977. Kanko Murayama and his colleagues first described a distinct sub type of duodenal endocrine tumor (somatastationama) with the bilection to affect at the sight of ampulla³.

Corresponding author *
Dr. Pramila R

Department of Pathology, Medical College Hospital & Research Centre (SRM Group), Tiruchirapalli, India
E Mail: lentonrahhu@gmail.com

There is association of duodenal somatostatinoma with NF1, pheochromocytoma and wanhipple lindau disease. Somatostatinoma refers to the tumor arising from D cell of pancreas. Somatostatin is involved in the inhibition of secretory release of peptide hormones⁴. The usual clinical syndromes associated with somatostatinoma are abdominal pain, nausea, dyspepsia, hyperglycemia, cholelithiasis and constipation². Misdiagnosis of the duodenal somatostatinoma as adenocarcinoma is quite common. The D cell neuro endocrine tumor because of cribriform growth pattern and presents of psammoma bodies rarely⁵.

The absence of pleomorphism the use of immune histochemistry avoids this diagnostic error. Rarely may they be multi centric and often >1cm limited to mucosa and submucosa. Mitotic is very minimal. Necrosis absent and they give positive diffuse cytoplasmic immunohistochemical staining for endocrine marker, synaptophysin due to the excess somatostatin release from the somatostatinoma. Here, we report a case of solitary duodenal somatostatinoma.

2. CASE DESCRIPTION

A 67 year old male was admitted in the tertiary care teaching hospital with the conditions of impaired digestion, heartburn, belching and upper abdominal pain. The patient also had nausea, anorexia and repeated diarrhea for several days. Endoscopy shows small sessile ulcerated polyp 1.5cm in size. The second part of the duodenal (Du2) biopsy is taken histopathological and immune histochemical studies carried out and reported as solitary duodenal somatostatinoma - glandular endocrine tumor of second part of duodenum.

Histopathological examination revealed the presence of uniform, round cells with round nuclei, salt and pepper chromatin, and thin rim of cytoplasm. Tubulo glandular differentiation and psammoma bodies were also observed (Figure 1). Further, the immunoperoxidase staining for synaptophysin in both low and high power showed diffuse cytoplasmic positivity (Figure 2).

Abdominal computed tomography showed a neuro endocrine tumour and polyps in the 2nd and 3rd part of the duodenum. Endoscopy revealed erosive gastritis with duodenal polyp with summit ulcer and suspected to gastrointestinal stromal tumour (Figure 3). Further biopsy confirmed the malignancy.

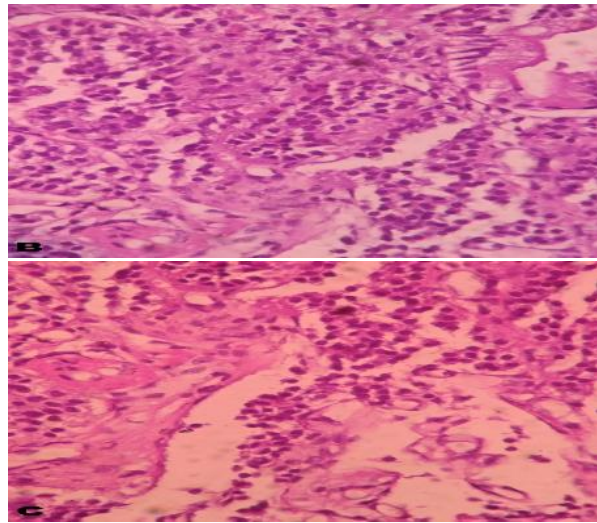
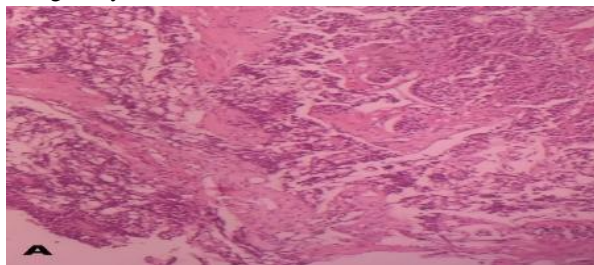


Fig 1: Histological section showing uniform, round cells with round nuclei

[A – Low power – Tubuloglandular differentiation and psammoma bodies; B & C – High power magnification revealed uniform, round cells with round nuclei, salt and pepper chromatin and thin rim of cytoplasm]

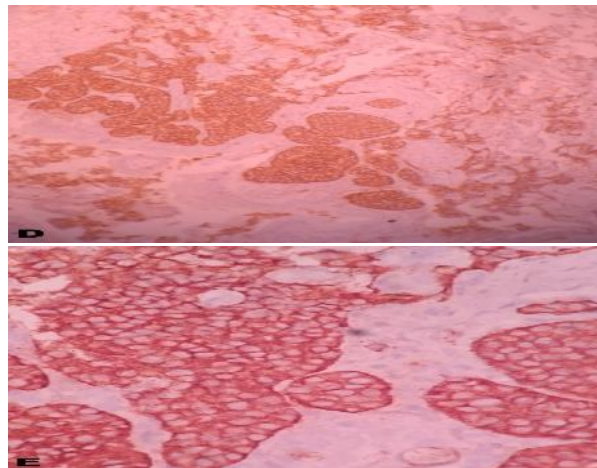


Fig 2: Immunoperoxidase staining for synaptophysin showing diffuse cytoplasmic positivity

[D – Low power; E – High power magnification of immunoperoxidation staining for synaptophysin – diffuse cytoplasmic positivity]

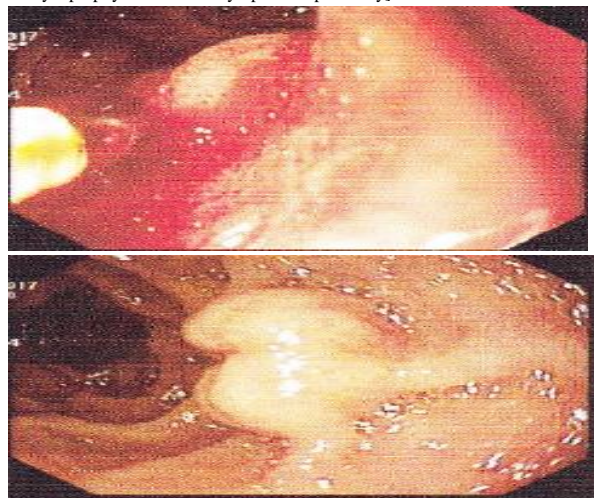


Fig 3: Endoscopic finding of the duodenal submucosa showed erosive gastritis

3. DISCUSSION

Among the neuroendocrine tumours, carcinoid tumors of the duodenum are generally low-grade and are largely involved in the expression of specific proteins, such as synaptophysin, neuron-specific enolase and chromogranin A. These tumors arise from enterochromaffin cells of the gastrointestinal tract that are composed of minimum fourteen different endocrine cell types. In the duodenum, this condition is nonfunctional, sporadic, well differentiated and slow growing and specially characterized as small bowel arise from the duodenum⁶. Duodenal carcinoids are most common in the proximal duodenum and present as early enhancing intraluminal polyps or mural masses where the symptoms are abdominal complaints including pain, nausea, vomiting and bleeding. For duodenal somatostatinomas, the somatostatin syndrome can occur only if the tumor is larger than 4 cms. Somatostatin is a cyclic tetradecapeptide secreted by the hypothalamus, cerebrum, spinal cord, vagus nerve and D cells in Langerhans islets of the pancreas, stomach, duodenum and small intestine⁷.

The hormone somatostatin inhibits gastric secretion and somatotrophin release. Nonspecific symptoms such as vague abdominal pain, nausea, weight loss, and altered bowel habits are more common than somatostatin syndrome and the specific syndrome occurs only with pancreatic somatostatinomas or extrapancreatic tumors larger than 4 cms. Duodenal somatostatinomas are observed smaller than pancreatic somatostatinomas and are frequently present with abdominal pain, obstructive jaundice, cholelithiasis, vomiting and abdominal bleeding, rather than typical somatostatin syndrome⁸.

The present case also presented like the same as the tumor is originated from the duodenum and the patient had only vague nonspecific symptoms. The required serum insulin, glucagon, gastrin, somatostatin and urine 5-hydroxyindoleacetic acid levels were not included and analyzed in this study. In general, the serum somatostatin level is elevated in functioning tumors, although duodenal somatostatinomas are usually non-secretory; thus the nonspecific symptoms and laboratory findings, microscopic and immune histochemical studies typically enable a specific diagnosis⁹.

The histological examination revealed uniform, round cells with round nuclei, salt and pepper chromatin and thin rim of cytoplasm. They have few mitoses with little necrosis and are separated by stroma. The most distinct histological characteristic of somatostatinomas is the psammoma body. Psammoma bodies were reported in 68% of duodenal somatostatinomas^{8, 9, 10}. By observing the malignant potential, further investigation and treatment specific to surgical resection is the recommended treatment for this tumor where the tumor size is 1 cm or smaller, endoscopic excision is adequate because of the low incidence of metastasis. In such cases, between 1 and 2 cm, transduodenal

excision should be applied whereas larger lesions are more aggressive and invasive¹¹.

The tumor larger than 2 cms produced high risk of metastasis in duodenal somatostatinomas. Further, if abnormal lymph nodes are detected, the tumor and all of the regional lymph nodes should be removed and this recommendation is based on the experience with duodenal gastrinomas, for which surgical resection of lymph node appears to improve survival. With liver metastases of neuroendocrine tumors, cytoreductive therapy, such as segmentectomy or lobectomy, is effective; thus somatostatinomas with hepatic metastases are suitable aspirants for hepatic resection^{8, 9}.

If supporting data are scanty, adjuvant chemotherapy for somatostatinomas is not recommended. There are only limited values for the palliative chemotherapy for unresectable and advanced tumors. Poly-medication with the combinations of streptozocin, fluorouracil, cyclophosphamide, or doxorubicin, produce limited responses in patients with metastatic disease. Octreotide is useful for reducing the symptoms of somatostatin syndrome. In most of the somatostatinomas cases with liver metastasis, there is the observation of 100% in tumors without liver or lymph node metastases.

4. CONCLUSION

Form this case study; it was understood that tumors of the periampullary region are considered highly malignant. The etiological evaluation, pathophysiology, clinical presentations and its associations, and importance of diagnostic imaging are discussed. The need of surgery and its importance in both the curative and palliative settings in conjunction with appropriate medical treatments are described. Management options depend on the extent of the disease and the cases are used to illustrate the rationale of such strategies.

5. REFERENCES

1. Masulovic D, Stevic R, Filipovic A, Micev M, Ivanovic A. Somatostatin producing duodenal carcinoma: clinicopathological description of a case. *Acta Chir Lugosl* 2013; 60: 61-4.
2. Kim JA, Choi WH, Kim CN, Moon YS, Chang SH, Lee HR. Duodenal somatostatinoma: a case report and review. *Kor J Int Med* 2011; 26: 103-7.
3. Tomita T, Friesen SR, Kimmel JR, Doull V, Pollock HG. Pancreatic polypeptide secreting islet cell tumors. A study of three cases. *Am J Pathol* 1983; 113: 134-42.
4. Soga J, Yakuwa Y. Somatostatinoma/ inhibitory syndrome: a statistical evaluation of 173 reported cases as compared to other pancreatic endocrinomas. *J Exp Clin Cancer Res* 1999; 18: 13-22.

5. Kenichi H, Giuseppe Z, Takayuki N, Akira T, Hiroshi K, Naoya N. Histopathology of gastrointestinal neuroendocrine neoplasms. *Front Oncol* 2013; 3: 2-7.
6. Mahajan SK, Mahajan LA, Malangoni MA, Jain S. Somatostatinoma of the ampulla of Vater. *Gastrointest Endosc.* 1996; 44: 612-4.
7. House MG, Yeo CJ, Schulick RD. Periampullary pancreatic somatostatinoma. *Ann Surg Oncol* 2002; 9: 869-74.
8. Tanaka S, Yamasaki S, Matsushita H. Duodenal somatostatinoma: a case report and review of 31 cases with special reference to the relationship between tumor size and metastasis. *Pathol Int* 2000; 50: 146-52.
9. Hoffmann KM, Furukawa M, Jensen RT. Duodenal neuroendocrine tumors: classification, functional syndromes, diagnosis and medical treatment. *Best Pract Res Clin Gastroenterol.* 2005; 19: 675-69.
10. Mullen JT, Wang H, Yao JC. Carcinoid tumors of the duodenum. *Surg* 2005; 138: 971-7.
11. Kelley T. Somatostatinoma. *Probl Gen Surg* 1994;11: 99-119

Conflict of Interest: None

Source of Funding: Nil